

Mumije: znanost i mit

Uranić, Igor; Čavka, Mislav; Petaros, Anja

Authored book / Autorska knjiga

Publication status / Verzija rada: **Published version / Objavljena verzija rada (izdavačev PDF)**

Publication year / Godina izdavanja: **2012**

Permanent link / Trajna poveznica: <https://um.nsk.hr/um:nbn:hr:300:474226>

Rights / Prava: [In copyright](#)/[Zaštićeno autorskim pravom.](#)

Download date / Datum preuzimanja: **2025-02-27**



Repository / Repozitorij:

[AMZdepo - Repository of the Archaeological Museum in Zagreb](#)



MUMIJE
znanost i mit

MUMMIES
science and myth

Nakladnik / Publisher

Arheološki muzej u Zagrebu
Trg Nikole Šubića Zrinskog 19
www.amz.hr

Za nakladnika / For the Publisher

Jacqueline Balen

Autor izložbe / Organised by

Igor Uranić, viši kustos / senior curator

Likovni postav / Exhibition design

Nikolina Jelavić Mitrović

Suradnici / Associates

Mislav Čavka, dr. med. / MD
Klinička bolnica Dubrava / University Hospital Dubrava
Anja Petaros, dr. med. / MD
Zavod za sudsku medicinu Sveučilišta u Rijeci /
Institute of Forensic Medicine at Rijeka University

Lektura / Proof Reading

Božena Bunčić

Prijevod / Translation

Agnes Milovan

Fotografije / Photographs

Filip Beusan, Mislav Čavka, Igor Krajcar,
Catherine Rutherford, Igor Uranić

Crteži / Drawings

Miljenka Galić

Oblikovanje i priprema za tisak / Design & DTP

Srećko Škrinjarić

Tehnička realizacija izložbe / Technical assistance

Ivan Troha, Robert Vazdar, Damir Zbukvić

Tisak / Press

Tiskara Zelina d.o.o.

Naklada / Print Run

500 primjeraka / copies

**Tiskanje kataloga i realizaciju izložbe
financijski su pomogli:**

Gradski ured za obrazovanje, kulturu i šport Grada Zagreba
i Ministarstvo kulture Republike Hrvatske

ISBN 978-953-6789-66-5

CIP zapis dostupan u računalnom katalogu
Nacionalne i sveučilišne knjižnice u Zagrebu
pod brojem 823638.

MUMIJE

znanost i mit

MUMMIES

science and myth





MUMIJE - ZNANOST I MIT

MUMMIES - SCIENCE & MYTH

ARHEOLOŠKI MUZEJ U ZAGREBU

ARCHAEOLOGICAL MUSEUM IN ZAGREB

Sadržaj

Contents

Igor Uranić	
Uvod	7
Introduction	
MITOLOGIJA VJEČNOG ŽIVOTA	13
THE MYTHOLOGY OF ETERNAL LIFE	
Putovanje na drugi svijet	14
Journey to another world	
Vječni život u doba piramida	26
Eternal life during the age of pyramids	
Demokratizacija vječnog života	34
Democratisation of Eternal Life	
Mumificiranje	38
Mummification	
Moderni svijet i mumije	55
Mummies and the modern world	
Literatura	59
Bibliography	
Mislav Čavka	
MUMIJE I ZNANOST	61
MUMMIES AND SCIENCE	
Mumije i radiologija	62
Mummies and Radiology	
Ljudske mumije iz Arheološkog muzeja u Zagrebu	67
Human Mummies from the Archaeological Museum in Zagreb	
Literatura	81
Bibliography	
Anja Petaros	
Mumije životinja	82
Animal mummies	
Životinjske mumije Arheološkog muzeja u Zagrebu	87
Animal Mummies of The Archaeological Museum in Zagreb	
Literatura	98
Bibliography	



Zagreb, Narodni Muzej

Mumija

Uvod

Introduction

Slučaj je htio da se u Zagrebu nađe nekolicina mumija nastalih u vrijeme faraonskog Egipta. Bilo je to u 19. stoljeću kad su Europljani, impresionirani ponovno otkrivenom faraonskom kulturom, počeli iz te zemlje dovlačiti što god bi pronašli stvarajući prestižne muzejske zbirke. Među zaljubljenicima u starine bilo je i ljudi s naših prostora. Jedan od njih bio je Mihael Barić koji je živio u Beču. Prilikom putovanja u Egipat u kojem je boravio 1848. i 49. godine, Barić je kupio egipatsku mumiju u lanenim povojima i odnio je u svoj bečki stan. Tamo je mumiju izložio svezavši je tako da stoji naslonjena na zid. Ne možemo točno znati u kakvom je stanju mumija bila, no Barića je nešto navelo da zaviri u njezine povoje. Možda su laneni povoji na nekom mjestu na mumiji bili oštećeni, ili dijelom odmotani. Inače, u tim je vremenima bio čest običaj otvaranja mumija u javnosti pred skupovima intelektualaca i zainteresirane publike. Dakako, to je ujedno značilo uništenje mumije, jer tada još nisu postojale neinvazivne metode kojima bi se u njih moglo zaviriti. Ipak, takve su “autopsije” nad mumijama omogućavale neke korisne spoznaje.

Općenito, arheologija i metode kojima se ona katkad služi može se promišljati kao skrnavljenje grobnica. No moderni svijet opravdanje za ovakve postupke nalazi u znanju i

A few mummies dating back to the period of pharaonic Egypt were found in Zagreb by chance. This took place in the 19th century when Europeans were impressed by the re-discovery of pharaonic culture and started shipping from that country everything they could possibly find leading thus to the creation of prestigious museum collections. Among antiquity lovers there were also people from the region of Eastern Europe, one of them being Mihael Barić, a Croatian antiquarian who lived in Vienna. During his trip to Egypt, where he stayed from 1848 to 1849, Barić bought an Egyptian mummy wrapped up in linen strips and took it to his Vienna apartment. Once there, he exhibited the mummy tied in such a way that it could stand by leaning against the wall. The exact condition in which the mummy was at that time cannot be inferred, but there was something that triggered Barić to take a peep into its bandages that were probably damaged or partly unwrapped. At that time it was quite customary to unwrap mummies in public in front of groups of intellectuals and the interested public, although this implied their destruction due to the fact that non-invasive methods for peeping into them did not exist. Still, such “autopsies” on mummies led to certain useful cognitions.

informaciji. Razvoje tehnologije omogućio je istraživanje bez uništavanja starina, a to se posebno odnosi na izučavanje mumificiranih tijela.

Što se Barića tiče, on je ipak mumiju razmotao samostalno ili možda u društvu prijatelja, a ne tijekom neke javne predstave. Lako je pretpostaviti da je bio nemalo iznenađen kad je na lanenim trakama u koje je mumija bila umotana pronašao tekst napisan crnom tintom. Ono što je pronašao postat će spomenikom nulte kategorije koji danas nazivamo *Zagrebačkom lanenom knjigom*¹, a riječ je o najdužem etruščanskom tekstu ikad pronađenom. Sam Barić toga nije bio svjestan. On je vjerovao da je pronašao nekakav egipatski zapis. Do spoznaje o jedinstvenosti i vrijednosti čudnih slova na povojima mumije došlo je tek 60 godina kasnije, kad je tekst pogledao njemački egiptolog Jakob Krall koji je shvatio njegovo pravo podrijetlo. Kasnije, mumija će postati poznata kao *Zagrebačka mumija*, zahvaljujući činjenici da je Mihaelov brat Ilija oba spomenika donirao Narodnom muzeju u Zagrebu. Bilo je to točno prije 150 godina - u svibnju 1862. godine. Nekoliko godina kasnije članovi ilirskog pokreta sakupili su novac za veliki otkup egipatske zbirke austrougarskog podmaršala Kollera koja se nalazila kod njegovih nasljednika u Pragu. Time je formirana Egipatska zbirka koja je danas u Arheološkom muzeju u Zagrebu.

Od vremena kad su Europljani započeli s istraživanjem Egipta mumije otkrivene u njegovim grobnicama privlače veliku pažnju. Hramovi, palače, utvrde i grobnice i u drugim starim civilizacijama djeluju impresivno, ali u Egiptu postoji još nešto – a to su mumije.

Fascinantno je u Kairskom muzeju vidjeti mrtva tijela velikih vladara Ramzesa II., Tutmozisa III. i drugih, čija djela su zapisana u povijesti. Ništa manje nisu zanimljive ni mumije plemića i običnih ljudi kojih su na tisuće sačuvane. Ne radi se samo o doživljaju strave i divljenja nad ljudskim tijelom starim više od 2000 godina. Mumije i istraživanje koja se

Generally speaking, archaeology and the methods it sometimes employs may be considered as defiling tombs. However, the modern world has found a justification for those measures in the fact that they provide knowledge and information.

The possibilities of conducting research without destroying antiquities have been increasing thanks to technologic development, and this particularly applies to the study of mummified bodies. As far as Barić is concerned, he unwrapped the mummy by himself or maybe with some friends, but not in the course of a public show. He must have been quite surprised at the sight of some text written in black ink that he discovered on the linen strips the mummy was wrapped in. What he discovered then was to become a monument of highest value and importance known today as *The Zagreb Linen Book*¹, i.e. the longest Etruscan text ever found. Barić himself was not aware of that fact: he believed that what he had found was an Egyptian document. It was as late as 60 years later, when the German Egyptologist Jakob Krall viewed the text realising its actual origin that a proper understanding of the uniqueness and value of the strange letters on the mummy's strips was gained. The mummy was to become known as the *Zagreb Mummy* and this thanks to the fact that exactly 150 years ago – in May 1862 Mihael's brother Ilija donated both monuments to the National Museum in Zagreb.

A few years later, members of the Illyrian Movement collected enough money to purchase a large Egyptian collection belonging to the Austro-Hungarian Lieutenant-General Koller that was stored with his heirs in Prague. It was by means of that action that today's Egyptian collection of the Archaeological Museum in Zagreb was created.

Mummies discovered in Egyptian tombs have been drawing much attention ever since Europeans started investigating Egypt. Although temples, palaces, fortresses and tombs have an impressive effect also in other ancient civilisations, Egypt has something more to it - mummies.

¹ O Lanenoj knjizi vidi: I. Mirnik - A. Rendić-Miočević: *Liber Lintevs Zagrabiensis, Vjesnik Arheološkog muzeja u Zagrebu (VAMZ)*, 1966. 3., s., XIX 40-71.

¹ About the Linen Book see: I. Mirnik - A. Rendić-Miočević: *Liber Lintevs Zagrabiensis, Vjesnik Arheološkog muzeja u Zagrebu (VAMZ)*, 1966. 3., s., XIX 40-71.

DA SE RIJEŠI TAJNA

U ARHEOLOŠKOM MUZEJU DOVRŠENO PRESNIMAVANJE
NAJVEĆEG ETRUŠČANSKOG NATPISA



JEDAN OD 86 SNIMAKA NA KOJE JE PRENET ETRUŠČANSKI NATPIS — SNIMLJENO OVIH DANA U ZAGREBU

ZAGREBAČKE MUMIJE

KAKO JE NA OVU MUMIJU DOSPIO POVOJAK S DRAGOCJENIM ETRUŠČANSKIM NATPISOM?



Arheološki muzej u Zagrebu ima u svojoj egipatskoj zbirci primjerak mumije koja je najprije pripadala kolekciji nekadašnjeg austrougarskog konzula u Beču Mihaila Barića. Dospjela je u ovaj muzej 1887. godine zaslugom biskupa Sirosmayera, koji ju je darovao zajedno s drugim predmetima. Mumija predstavlja mladu Egipćanku. pretpostavlja se da je imala manje od 30 godina, a mogla bi biti stara više od 2000 godina.

Mumija je vrlo dobro očuvana. Nije poznato kako ju je Barić nabavio. Prema jednoj verziji kupio ju je u New Yorku kod nekog starotinarra, a po drugoj ju je nabavio za vrijeme svog putovanja u Egipat. Mumija ima na sebi povojke, na izvanrednu vrijednost kojih nitko nije ni pomišljao. Tek kada je poznati egiptolog Brugsch pregledao, otkrio je da se na njoj nalaze neki natpisi, ali da oni nisu egipatskog porijekla (Brugsch je dobio od egipatske vlade titulu „pašee“ zbog odličnog poznavanja egiptologije). Tek 1892. godine prof. Krall publicirao je svoj naučni rad u kome iznosi autentične dokaze da su povojci, kojima je bila omotana ova mumija, zapravo najveći primjerak etruščanskog natpisa koji je uspjelo sačuvati do danas na svijetu.

Od tada je taj povoj predmet neprekidnog zanimanja učenjaka koji se bave proučavanjem Etruščana. Nikome još nije uspjelo da pronikne tajnu etruščanskog jezika, jezika naroda koji je živio na području Toskane, u današnjoj Italiji, do početka naše ere. Njihova civilizacija je nestala, a spomenici koji su ostali služe da se više pronikne u život tog naroda. Među nepoznanice svakako spada njihov jezik.

Arheološkom muzeju neprekidno su stizale molbe učenjaka da im se omogući upoznati jedinstveni pisani tekst Etruščana. Na žalost, to nije bilo moguće. Platno na kome se on nalazi dugačko je 15 metara i mora se uvijek čuvati na istoj temperaturi.

Češće pokazivanje na svjetlu oštetilo bi ga. I inače su pojedini njegovi dijelovi zamrznjeni i pomalo načeti zubom vremena. Za posljednjih 17 godina ovaj povojak mumije neprocjenjive vrijednosti izvađen je iz svoje specijalne kutije samo triput.

Ipak, Arheološki muzej uspio je ovih dana smisliti čitav tekst na posebnim infracrvenim pločama. Taj posao obavila je Vera Vejvoda, viši kustos, u suradnji s fotografom Ureda za kriminalistička ispitivanja SRH Ivanom Lukanom, pa je u cijelosti presnimljen ovaj etruščanski tekst. Snimci su izvanredno jasni, dapače čitljiviji nego na povoju. Bio je to veoma naporan posao, koji je trajao više od dva mjeseca,

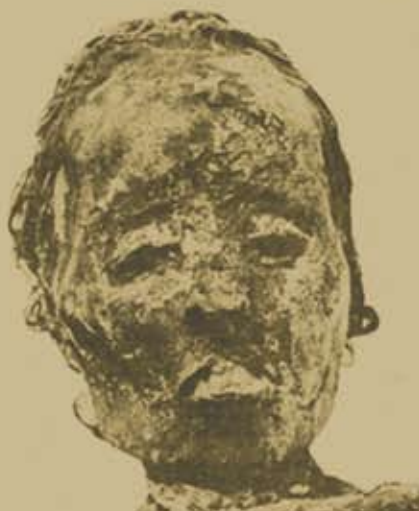a zahtijevao i znatna materijalna sredstva. Treba imati na umu da je načinjeno 86 snimaka, od kojih je svaki zahtijevao dugotrajnu ekspoziciju. Poseban problem je bio kako sačuvati povojak od eventualnih oštećenja za vrijeme snimanja. Konačno, Arheološki muzej sada raspolaže s kopijom tog teksta, koji može slati učenjacima, da se dalje, i sada prvi put, u cijelosti mogu baviti njegovim proučavanjem.

— Jedan snimak stoji nar oko 20 dolara — kaže Vera Vejvoda. — Raduje nas da je uspjelo dovršiti ovo presnimavanje i da sada možemo učenjacima omogućiti ostvarenje njihove davne želje, da posjeduju ovaj rijetki tekst.

— Neprekidno dobivamo molbe od najpoznatijih ustanova koje se bave etruščanskim zagonetkama, ali iako je prošlo već 80 godina otkako ovaj raritet posjedujemo, tek ćemo sada biti u mogućnosti da ga učenjacima damo na obradu, ističe Ivica Degenčić, viši naučni suradnik.

Tako će, zahvaljujući ovoj inicijativi Arheološkog muzeja, koja je u naučnom svijetu primljena s mnogo pohvala, biti načinjen korak naprijed u pokušaju da se otklonetne tekst ovog jedinstvenog primjerka etruščanskog natpisa. Možda ćemo, uz ostalo, jednoga dana doznati — kako je ovaj povoj s etruščanskim tekstom dospio na egipatsku mumiju?

B. DORDEVIĆ





na njima obavljaju daju sve više novih uvida u život ljudi u starom vijeku. One otvaraju novu dimenziju u znanosti čineći povijest egzaktnijom nego ikad ranije. Upoznajemo njihovu tjelesnu građu, bolesti, ishranu, medicinu, običaje i još mnogo toga što bez mumija ne bi bilo moguće.

S druge strane, nevjerojatna je i sama ideja vječnog života za kojim su težili Egipćani. Kozmički eternalizam ondje je bio suprotstavljen ovozemaljskom determinizmu. Želju da se postigne vječno duhovno oslobođenje u nevidljivom tijelu što su ga nazivali *akh*, moglo se, kako su vjerovali, postići samo ukoliko je tijelo nakon smrti bilo mumificirano. Iz tog se vjerovanja otvara tema mitologije zagrobnog života koja je u egipatskoj kulturi vrlo detaljno razrađena kroz pogrebnu literaturu i magiju postupaka, čarobnjačkih izričaja, ritualnih radnji i molitvi koje su pratile obradu, mumificiranje i balzamiranje tijela svake umrle osobe. Sve to čini zbir predodžbi koje se oslanjaju na postojanje duše koja će se osloboditi iz tijela, izići iz grobnice i kretati se po zemaljskim i nebeskim prostranstvima. Izvori ovih ideja su *Tekstovi piramida*, *Tekstovi sarkofaga* i *Knjige mrtvih*, koji u mnogo različitih varijanti opisuju taj tajanstveni put takozvanog “izlaska na dan” i život oslobođene duše.

Izložba “Mumije – znanost i mit” povezuje dvije strane, dva aspekta i pogleda na tematiku mumija. Znanost - paleoradiologiju mumija s jedne, i egipatski mit o zagrobnom životu s druge strane.

“ZAGREBAČKA MUMIJA”

Izložena je u zasebnoj prostoriji uz stalni postav Egipatske zbirke. Riječ je mumiji poznatoj pod tim imenom diljem svijeta.

“THE ZAGREB MUMMY”

Exhibited in a separate room as part of the permanent exhibition of the Egyptian collection. It is by that name that the mummy is known all around the world.

In fact, what is fascinating in the Cairo Museum are the dead bodies of major Egyptian rulers such as Rameses II, Thutmose III and others, whose actions are recorded in history, but not less interesting are the thousands of preserved mummies of noblemen and common people. When looking at them, one does not experience only fear and fascination with human bodies that are more than 2000 years old, but one gains also new insights into the life of the people of the Ancient era. Mummies conveyed a new dimension to science making history more precise than it was ever before. It is thanks to those mummified bodies that we were able to find out the bodily structure, illnesses, diet, drugs, customs and many other things concerning the people of the Ancient era, which would have been impossible to discover otherwise.

On the other hand, the very idea of eternal life towards which Egyptians strived, is unbelievable. Cosmic eternalism was there juxtaposed to this-worldly determinism. The wish to attain eternal spiritual freedom in an invisible body, which they called *akh*, could be realised, according to their belief, only if the body was mummified after death. It is from that belief that the mythology of the afterlife developed and in the Egyptian culture mythology was elaborated into detail in the funerary literature and the magic of procedures, in magical spells, ritual activities and prayers that accompanied the treatment, mummification and embalming of the body of every person. All this represents the whole of conceptions relying on the existence of a soul that will be freed of the body, leave the tomb and travel through earthy and heavenly spaces. The origins of those ideas are found in the Pyramid Text, the Coffin Texts and the Books of the Dead, which depict in various ways the secret path of the so-called “coming forth by day” and the life of a freed soul.

The exhibition “Mummies – Science and Myth” incorporates two sides, two views and aspects of the topic on mummies: science and the paleo-radiology of mummies on the one side and the Egyptian myth of the afterlife on the other.



Mitologija vječnog života
The mythology of eternal life

Igor Uranić

Putovanje na drugi svijet

Journey to another world

Staroegipatske zamisli o životu nakon smrti temelje se na esencijalističkoj ideji o postojanju nevidljivog dijela stvarnosti koji se krije u svim stvarima. Esencija je prema mitovima u vrijeme stvaranja svijeta istekla iz oka boga Sunca i formirala ljudska bića. Budući da potječe od njega esencija ljudskosti je vječna i smrt ljudskog bića, baš kao i rođenje, za nju predstavlja samo novu etapu transformacije. Ta esencija, kad je riječ o čovjeku, nije jednostavne strukture. Čovjekova nevidljiva kopija, mogli bismo reći duh ili dvojnik,² naziva se *ka*. Osim čovjeka *ka* posjeduju i bogovi, i životinje, pa čak i neživi predmeti. Katkad se *ka*, koji je smješten u srcu, može promišljati i kao tjelesni aspekt duše.

² Tumačenje pravog značenja *ka* u stvarnosti je vrlo složeno. Taj pojam u biti ne odgovarava ni jednoj predodžbi u kršćanskoj uljudbi, pa je svaki njegov prijevod donekle problematičan. U nekim kontekstima umjesto 'duša' pojmu *ka* više bi odgovaralo "svijest", "prisutnost" ili pak, "dvojnik".

Ancient Egyptian concepts of the afterlife rely on the essentialist idea about the existence of an invisible part of reality that is hidden in all things. According to myths, at the time of the creation of the world, the essence was poured out from the eye of the Sun god thereby creating human beings. Since it was originated from him, the essence of manhood was held to be eternal with both the death and birth of human beings representing only a new stage in the transformation of the essence. When it came to men, this essence did not have a simple structure. Men's invisible copy, we could say their spirit or a look-alike², was called *ka*. Alongside men, also gods, animals and even inanimate objects possessed a *ka*. Sometimes the *ka*, which was placed in the heart, may be perceived as a bodily aspect of the soul.

² The interpretation of the real meaning of *ka* is very complex. Since this concept actually does not correspond to any concept in Christian civilisation, any translation of that concept is problematic to a certain extent. In certain contexts instead of "soul" the terms "consciousness", "presence" or "copy" would be more appropriate as a translation of the concept of *ka*.

Druga sastavnica složene ljudske esencije jest komponenta zvana *ba*. Dok se *ka* u hijeroglifskim zapisima prikazuje kao uzdignute ruke

𓀀, *ba* se javlja u obliku ptice s ljudskom glavom 𓀀, no isto tako on³ može biti čaplja 𓀀 ili 𓀀 ovan. Dok je *ka* pretežno magijski pojam tipičan za religiju starog vijeka, *ba* je mnogo bliži ideji duše u promišljanjima zapadne kulture i teologije. Prema egipatskoj eshatologiji ovi elementi preživljavaju smrt materijalnog tijela. *Ka* ostaje u blizini mumi-je i grobnice, uživajući u darovima koji mu se prinose, dok se *ba*, za razliku od njega, uzdiže u nebo.

Nakon osvješćivanja i revitalizacije životnih funkcija (kretanje, govor, sluh i vid) nevidljivi duh izlazi iz grobnice i suočava se s vaganjem duše. Ova mitska scena odvija se ispred prijestolja Ozirisa, boga zagrobnog svijeta, i njegovih četrdeset i dvaju sudaca. Srce umrlog stavlja se na vagu božice istine Maat. Oziris u bijeloj odori sjedeći na tronu promatra obred

³ I *ka* i *ba* u egipatskom su jeziku muškog roda.

The second element of the complex human essence was the component called *ba*. In hieroglyphs *ka* was represented as a pair of raised arms 𓀀, *ba* was depicted as a human-head-

ed bird 𓀀, but it³ could be represented also as a heron 𓀀 or a ram 𓀀. Whereas *ka* was predominantly a magic concept typical of the religion of the Ancient era, *Ba* is much closer to the (Western religions) notion of souls present in the thought of Western culture and theology. According to Egyptian eschatology, these elements survived the death of the material body and while *ka* remained in the vicinity of the mummy and the tomb enjoying the offerings presented to it, *ba* ascended to the heavens.

After becoming aware and revitalising vital functions (movement, speech, hearing and sight) the invisible spirit left the tomb and faced the weighing of the soul. This mythological scene took place in front of the throne of Osiris, the god of the underworld, and his

³ In Egyptian the gender of both words, *ka* & *ba*, is male.





držeci u rukama kraljevsko znakovlje, a na glavi mu je bijela kruna *heđet*. Umrlu osobu dovodi jedan od bogova – Tot s glavom ibisa ili Anubis s glavom čaglja. Kad je srce stavljano na jednu stranu vage, a pero Maat na drugu, i vaga pokazuje jednakost, pokojnik će biti presuđen kao *maa-heru* onaj čija je riječ istinita. No, prije toga, stojeći pred Ozirisom, on negira svoje grijeh. Ono što izgovara napisano je u 125. poglavlju *Knjige mrtvih*:⁴

*Ne počinih ja grijeha prema ljudima
Ne naudih ja svome narodu
Ne zamijenih ja grijeh za pravednost
Ne govorih ja protiv Boga
Ne uvrijedih ja siromašne
Ne učinih ja ništa čega se gnušaju bogovi
Ne optužih slugu pred njegovim nadređenim
Ne uzrokovah bolest
Ne mučih glađu
Ne tjerah u plač
Ne ubih
Ne naredih ubojstvo
Ne pričinih bol
Ne uskratih ja žrtve hramovima
Ne opsovah ja kruh božji
Ne ukradoh ja od žrtvi akhuovima
Ne počinih bludan odnos s dječakom
Ne bijah ja sitničav
Ne otuđih ni komad kruha.*

Scena vaganja srca koja po moralnoj poruci koju sadrži podsjeća na posljednji sud pred Kristom u *Novom zavjetu* (*Mt* 25, 31), ima i svoju magijsku stranu. Naime, ljudi iz naroda uvjereni u djelovanje magije vjerovali su da se vaganje duše može malo “namjestiti”, kako bi se osiguralo da pokojnik bude proglašen pravednikom (eg. *maa-heru* “onaj čija je riječ istinita”). U tu svrhu koristio se amulet skarabeja srca. Takvi skarabeji izrađivali su se od kamena. Najčešće riječ je o serpentinitu, bazaltu i pješčenjaku, a na njihovu donju plohu urezivao se tekst 30. poglavlja *Knjige mrtvih*. Taj tekst trebao je uvjeriti srce (koje taj skarabej predstavlja) da ne svjedoči protiv pokojnika. Dakle, srce je ovdje shvaćeno kao instrument koji čuva zapis istine (u kojem, kako smo spomenuli, boravi dvojniki *ka*).

⁴ Prijevod iz: I. Uranić, *Stari Egipat*. Zagreb, 2002, 243.

forty-two judges. The heart of the deceased was placed on the scales of Ma'at, the goddess of truth. Sitting in his throne in a white gown Osiris observed the ritual holding the royal symbols of a crook and a flail in his hands and wearing a white crown – *hedjet* – on his head. The deceased was then brought in by one of the gods – an ibis-headed Tot or a jackal-headed Anubis. If the scales showed equality, once the heart of the deceased was placed on one side of the scales against Maat's feather, the deceased was judged as *maa-heru* – “the true of voice”, however, before that standing before Osiris, the deceased rejected his sins by pronouncing the following lines written in Chapter 125 of the *Book of the Dead*:⁴

*I have not committed wrong doing against anyone;
I have not mistreated cattle;
I have not injustice in the place of Truth
I do not know that which should not be
I have not done evil
I have not made a daily start in labours over
what I did (previously);
My name has not reached the office of director
of servants;
I have not debased a god;
I have not done the abomination of the gods;
I have not deprived an orphan;
I have not done that what the gods abominate
I have not slandered servant to his superior
I have not caused pain
I have not caused weeping
I have not killed
I have not commanded to kill
I have not made suffering for anyone
I have not diminished the offering loaves in the
temples
I have not damaged the offering cakes of the gods*

In terms of the intrinsic moral message, the weighing of the heart reminds us of the final judgement before Christ in the New Testament (*Mt* 25, 31), but it also has its magical side. In fact, convinced in the effects of magic, the people of the folk believed that the weighing of the soul could be slightly “adjusted” in order to ensure the deceased to

⁴ Ch. Maystre, *Les declarations d'innocence*. Le Caire 1973. 23.

No izgovaranje čarobnog teksta može ga navesti da svjedočenje bude poželjno – dakle da je pokojnik nevin. Ipak, kraj teksta kaže “ne izusti laž”, što znači da podrazumijeva nevinost pokojnika. Tekst⁵ kaže:

*Srce moje, majko moja. Srce moje, majko moja.
Srce moga postanka u grudima mojim.*

Ne ustani svjedokom protiv mene.

Ne protivi mi se pred velikim vijećem bogova.

Ne suprotstavi mi se pred čuvarem božanske vage.

Ti si ka u mome tijelu.

Hnum je zaštitio dijelove moga tijela.

Ti izlaziš na prelijepo mjesto koje ti je pripravljeno.

Neka moje ime ne zaudara pred sucima

Koji prosuđuju ljudska djela.

Dobro li je čuti srce časnog čovjeka na saslušanjju.

Ne izusti laž pred licem velikog boga Khenti-Uentija.

Nakon odbacivanja grijeha jedan od dvojice bogova, Tot ili Anubis, dovodi dušu umrloga pred Ozirisa koji mu dozvoljava ulazak u Amenti. Za svaki slučaj uz vagu stoji demon Ammut – strašna božica krokodilske glave, tijela koje je kombinacija nilskog konja, lava i leoparda. Njezin epitet je značenja “ona koja proždire”. Ammut će požderati srce onoga tko nije presuđen kao pravednik, što automatski znači da za njega nastupa druga smrt. Duša koja ne posjeduje srce ne može opstati u astralnom svijetu Duatu. Čak i nakon što je već ušao u Duat srce umrle osobe vrebalo mnoštvo demona koji ga žele istrgnuti i pojesti. Zato je i srce zaštićeno mnogobrojnim bajalicama i magijskim izričajima. Neke od njih nalaze se u 27. i 28. poglavlju *Knjige mrtvih*. Ovako govori vlasnik *Papirusa Zagreb 601*, pisar Idedtu-Khonsu-Kheper, koji želi obraniti svoje srce od zlih ratničkih bogova iz Heliopola:

⁵ Prijevod: I. Uranić, *Prilozi o skarabjima srca*. VAMZ XXIV – XXV, 1991-91, 254.



SKARABEJI SRCA I AMULETI KOJI PRIKAZUJU SRCE

U osnovi vjerovanja povezanim s tim važnim organom koji čuva *ka*, po nekima dušu, odnosno, svijest ili budnu nazočnost, je predodžba prema kojoj će kameno srce ili amulet preuzeti tu ulogu od organa koji ju je obavljao za života. To osobito vrijedi za skarabeje srca čija se moć pojačava magijskim tekstom koji se na njih urezivao. I ovdje raspoznajemo jednu od karakterističnih izvornih zamisli Egipćana o snazi napisane i izrečene riječi. Riječ je osobito moćna u stvarnosti drugog svijeta, gdje se izrečene namjere.

HEART SCARABS & AMULETS REPRESENTING THE HEART

At the heart of the belief connected to this vital organ protecting *ka* and considered by some the soul, consciousness or the awake presence, is the notion that the stone heart or amulet will take over the role that organ used to perform during the lifetime of the deceased. This is particularly true of heart scarabs, whose power was strengthened by the magical text engraved on them. In this example, one of the typical and originally Egyptian notions concerning the power of the written and spoken word may be recognised. The word is particularly powerful in the reality of the afterlife, where pronounced intentions are materialised.







be proclaimed a righteous man (eg. *maa-heru* “the true of voice”). For that purpose, the amulet of a heart scarab was used. Such scarabs were made of stone, mostly serpentine, basalt and sandstone, whereas on their lower surface the text of chapter 30 in the *Book of the Dead* was engraved. The text was meant to convince the heart (represented by the scarab) not to testify against the deceased. In fact, the heart is conceived here as an instrument storing the record of truth (which is inhabited by ka). However, pronouncing the magical text may induce it to testify in a desirable way, i.e. that the deceased is innocent. Still, the end of the text reads “do not pronounce a lie”, which means that the innocence of the deceased is presumed. The text⁵ reads as follows:

*My heart, my mother; my heart, my mother.
My heart of my life upon earth.
May naught rise up against me in judgment in
the presence of the lord of the trial;
let it not be said concerning me and of that
which I have done.
“He hath done deeds against that which is
right and true”;
may naught be against me in the presence of
the great god, the lord of Amenti.
Homage to thee, O my heart! Homage to thee,
O my heart!
Homage to you, O my reins! Homage to you, O
ye gods who rule over the divine clouds,
and who are exalted by reason of your sceptres;
Speak ye comfortably unto Ra, and make me to
prosper before Nehebka”.
And behold him, even though he be joined to
the earth in the innermost parts thereof, and
though he be laid upon it, he is not dead in
Amenti, but is a glorified being therein.*

After the deceased has rejected their sins, their soul is accompanied by either Thoth or Anubis and taken to Osiris, who allows the deceased to enter the Amenti. Just for good measure, demon Ammut stands alongside the scales. Ammut is a horrible crocodile-headed goddess whose body is a combination of a hippopotamus, a lion and a leopard.

⁵ Naville, *Todtenbuch*, Bd. I., Pl. XL., XLII., XXXIX.



Poglavlje 27⁶

Izričaj kojim se ne dopušta da bude oduzeto srce Ozirisu svećeniku boga Amona Iđedtu-Khonsu-kheperu, čija je riječ istinita:

“O, ti koji otimaš i koji čupaš srca: Jer to je ono što se događa sa srcem čovjeka prema njegovim djelima, bez njegova znanja o njima. Pozdravljam vas, gospodari vječnosti heh i vječnosti đet! Nemojte oteti ovo moje srca u ovoj godini, u ovom mjesecu [...] nikad!”

Poglavlje 28

Izričaj kojim se ne dopušta da bude oduzeto srce Ozirisu svećeniku boga Amona Iđedtu-Khonsu-kheperu, čija je riječ istinita koji je u nekropoli:

“O, Lavlji bože! Ja sam korijen. Ono što izbje-gavam je ući u božje dvore. Ne dopuštam da mi otmu ovo moje srce ratnici iz Heliopola. O, ti koji spravljaš odjeću Ozirisovu! On vidje Seta. O, ti koji su ga porazio i odbio njegove nepri-jatelje! Ovo srce sjedi i plaće pred Ozirisom. Njegov štap je njegovoj ruci. Ja mu predajem skrivene stvari moga srca u hramu onoga čije je lice široko. Ja sam za njega zagrabilo pijesak pred vratima Hermopola. Ovo moje srce neće biti oduzeto. Ja sam onaj čija mjesta ćete napu-stiti zbog njega. Srca su okovana na Poljima go-dišnjih žrtava. Budite snažni kako biste odoljeli svakoj odvratnosti koja odnosi vaša srca u va-šem satu iz vaših šaka. Vaše ruke nadvladavaju snažnog. Moje je srce u Analima Atuma, bilo da ga on vodi u Setovu jazbinu ili ne. On je tamo darovao meni moje srce koje bijaše stvoreno po njegovoj želji (i prema želji) vijeća bogova koji su u nekropoli.”

Kako duša potječe od Sunca, ona mu se nakon smrti nastoji vratiti kako bi se stopila s tim najvažnijim božanstvom staroegipatske kulture. Kad je uzletjela na nebo duša umrlog ulazi na barku kojom Sunce plovi po nebu i kreće na putovanje u kojem će doživjeti sve transformacije kroz koje prolazi i sam bog Sunca Ra. Kad barka zađe za zapadni horizon, koji simbolizira ulaz u zemlju mrtvih (eg. Amenti), sunce se mijenja iz čovjeka s

⁶ Prijevod objavljen u: I. Uranić, *Book of the Dead Papyrus Zagreb 601. Studien der Altägyptischen Kultur* 33, Hamburg. 2005; S. 357-371, Taf. 27-32.

The meaning of her name is “the one who devours”. Ammut would devour the heart of the one who would not be judged as a righteous man, which automatically meant dying a second death: a soul that did not possess a heart could not live in the astral world of Duat. Even after entering the Duat, many demons revon the heart of the deceased wishing to wrest and eat it. That is why the heart is protected by numerous spells and magical utterances. Some of those are found in chapters 27 and 28 of the *Book of the Dead*. This is how the owner of the Papyrus Zagreb 601, scribe Iđedtu-Khonsu-Kheper speaks wishing to protect his heart from the evil gods of war of Heliopolis:

Chapter 27⁶

Spell for not allowing to be carried away the jb-heart of Osiris, the Wab-priest of Amon Idjedtu-Khonsu-kheper, the true of voice:

“Oh, you who take the ib-heart and tear out the haty-hearts: That is what became of [the jb-heart] of a man according to his deeds, without him knowing it. Hail to you the lords of heh eternity, the founders of eternity! Do not take away my heart in this year, in this month..., nor ever!”

Chapter 28

Spell for not allowing to be carried away the heart of Osiris, the Wab-priest of Amon Idjedtu-Khonsu-kheper, the true of voice, from him in the necropolis.

Oh, Lion-god! I am a root. My abomination is the slaughtering-block of the god. This heart shall not be taken away from me by the fighters of Heliopolis. Oh, maker of clothes of Osiris. He has seen Seth. Oh, turn back in pursuit of him who smote him and remove for him (his) enemies. This heart sits and weeps (itself) before Osiris whose staff is in his hand. I have given to him the hidden things of the heart in the temple of the One who's face is wide and he has presented sand at the entrance to Hermopolis.

⁶ Published in: I. Uranić, *Book of the Dead Papyrus Zagreb 601. Studien der Altägyptischen Kultur* 33, Hamburg. 2005; S. 357-371, Taf. 27-32.

glavom sokola, postaje čovjek s glavom ovna i u tom obliku putuje podzemnim svijetom koji je u stvari tijelo božice neba Nut. Solar- na barka nailazi na mnoge prepreke – bogove i demone koji joj se suprotstavljaju, ali i one koji joj pomažu. Na kraju Sunce uzlazi u obli- ku skarabeja Khepri koji gura njegovu kuglu i ponovno se rađa na istočnom horizontu (eg. Jabti). Također i duša se obnavlja i ulazi zajedno sa suncem u novi ciklus postojanja. Nut guta Sunce i nebeska tijela i ponovno ih rađa svakog dana.

Čovjek je, dakle, dijelom velikog kozmičkog ciklusa rađanja i umiranja u kojem sudjeluje zajedno s nebeskim tijelima. O tome svjedoči i izraz “roditi se” koji u jednoj varijanti do- slovce znači “promijeniti stanje”.

This heart of mine shall not be taken away. I am the one those whose places you have advanced binding hearts to him in the field of fresh offerings. (Get) strong to oppose every abomination of him, oh rescuer of your Kas. Your might is in your grasp because your two arms are behind you. It is this heart in the annals of Atum, it leads to the holes of Seth. Will he not give it to me those who are in my heart and who my heart has created ... in the necropolis.

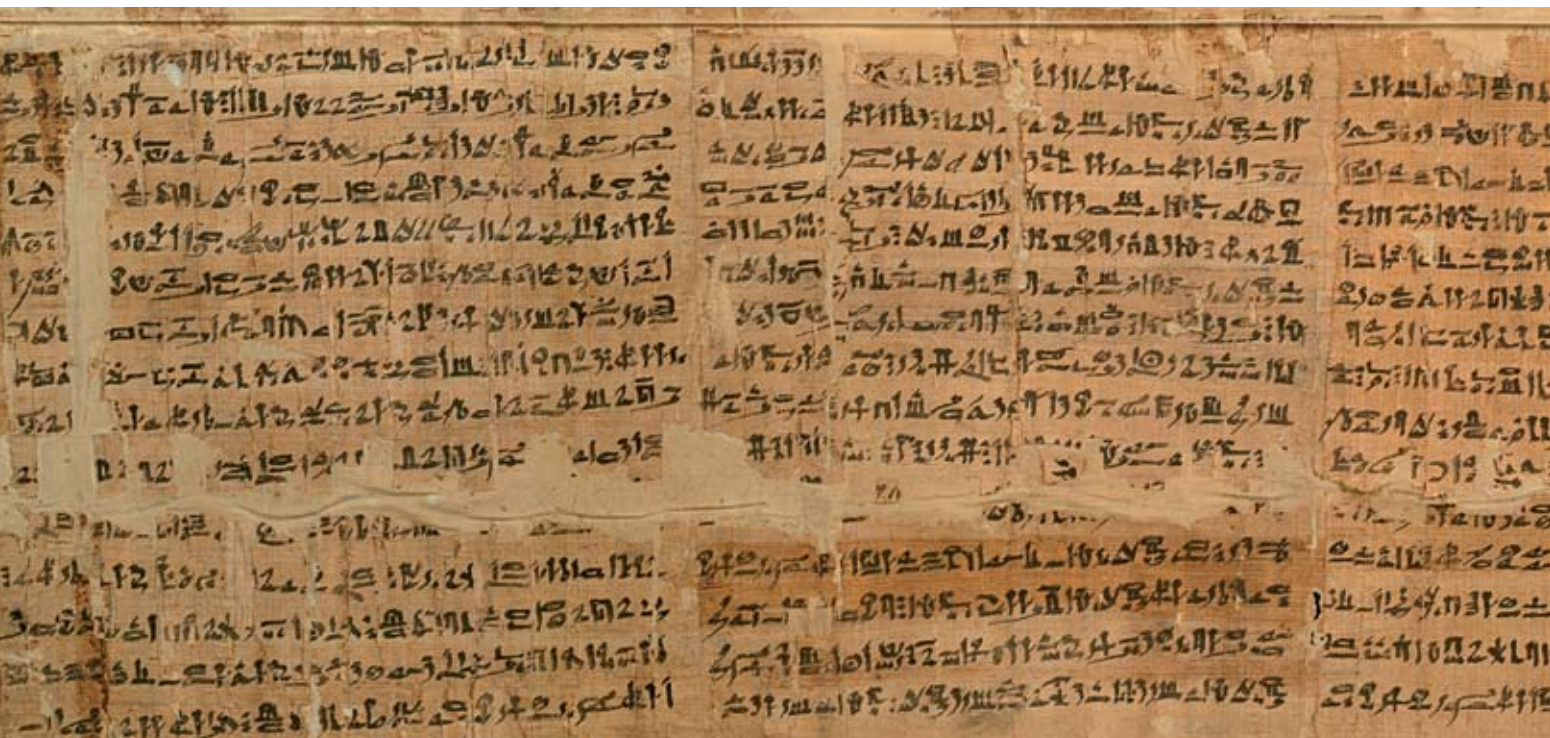
Since the soul originates from the sun, it seeks to return to it after death in order to unite with this most important deity of Ancient Egyptian culture. Once it flies into the sky, the soul of the deceased enters the ship on which the sun floats in the sky and starts a journey in which it will experience all the transformations the very sun god Ra goes through. Once the ship leaves the western horizon, which symbolises the entrance into the land of the dead (eg. Amenti), the sun is transformed from a falcon-headed man to a ram-headed man and in that shape travels though the underworld which is actually the body of Nut - the goddess of the sky. The solar ship faces numerous obstacles – gods and demons that oppose it, but also those who help it. Finally, the sun rises in the form of a Khepri scarab that pushes his ball and is newly born into the eastern horizon (eg. Jabti).

“KNJIGA MRTVIH”

Iđed-tu-Khonsu-khepera
iz Arheološkog muzeja u Zagrebu

“BOOK OF THE DEAD”

Iđed-tu-Khonsu-kheper
from the Archaeological Museum in Zagreb



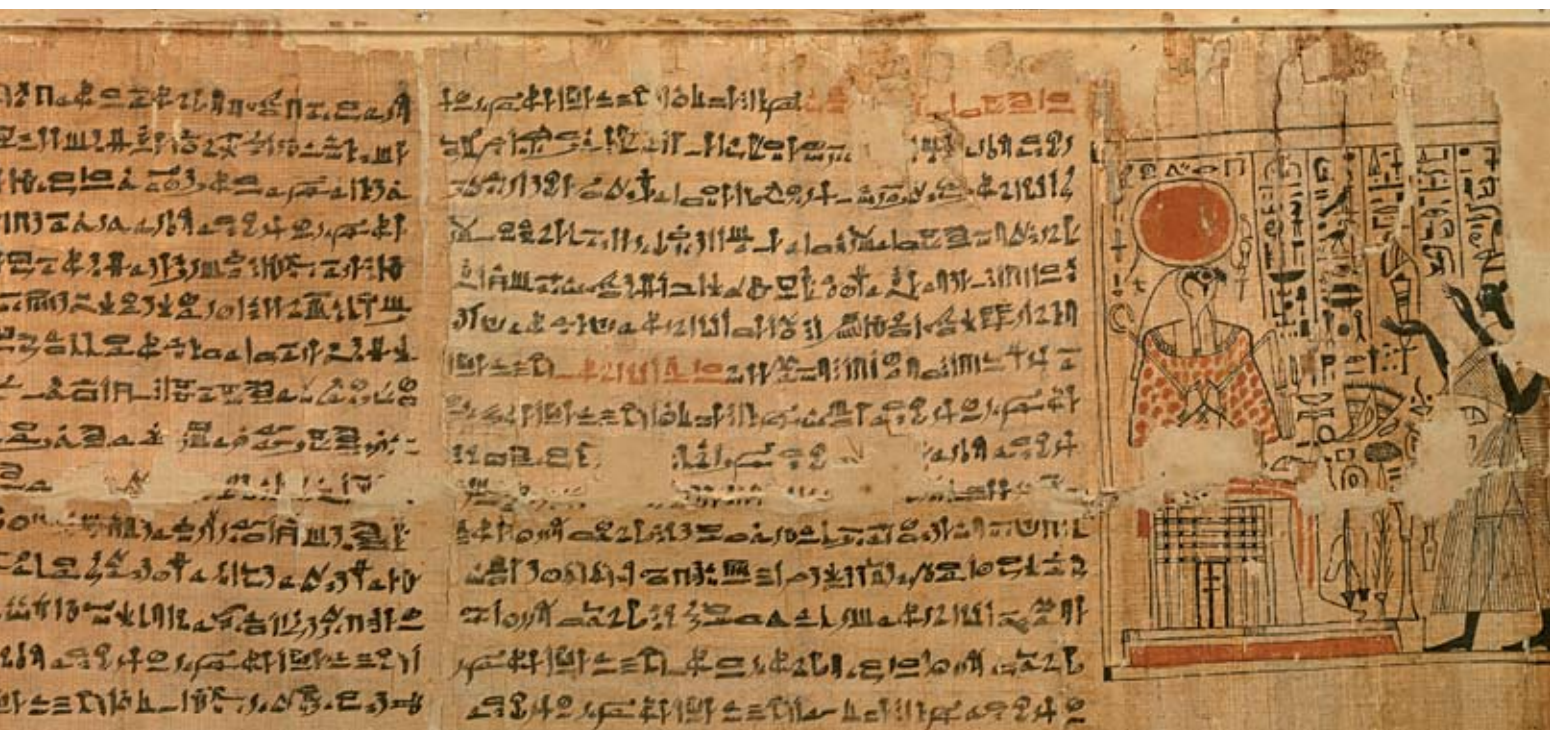


The soul is also renewed and enters, together with the sun, in a new cycle of existence. Nut swallows the sun and the celestial bodies to give birth to them every day anew.

Man is thus a part of the large cosmic cycle of birth and death in which it participates together with the celestial bodies. This is witnessed by the term “to be born” which in one variety literally means “to change one’s condition”.

KHUFUOVA SOLARNA BARKA, Muzej u Gizi
THE SOLAR BOAT OF KHUFU, Giza Museum

RA PLOVI NEBOM na barci
RA FLOATING THROUGH THE SKY on the boat



Vječni život u doba piramida

Eternal life during the age of pyramids

Početak trećeg tisućljeća u egipatskom se graditeljstvu javlja ideja piramide. Smatra se da je prva bila izgrađena piramida faraona Đosera u Sakari, nedaleko od Kaira, a potom još nekoliko u Dahshuru i Meidumu. Nakon toga je uslijedio mega projekt triju velikih piramida u Gizi. Iako mnogi drže da piramide nisu bile isključivo faraonske grobnice smatra se da je do njihove gradnje u svakom slučaju došlo pod utjecajem vladara koji su svoj uspon na nebo smatrali nastavkom vladavine nakon smrti. U svakom slučaju te su građevine izraz sposobnosti i tehnološkog napretka ukupnog društva faraonske države, kao i duha koji je slavio vječnost prikazanu u kamenu. Tri velike piramide ne pružaju nam mnogo podataka o egipatskom promišljanju i teorijama o zagrobnom životu. Na njima, kao ni u njima, nema uklesanih tekstova. No kad je riječ o malim piramidama 5. i 6. dinastije situacija je bitno različita. One su, naime, prave riznice naših saznanja o eshatologiji, teologiji i životu duše po Egipćanima. *Tekstovi piramida* pronađeni su u malim piramidama smještenim nadomak Đoserove stubaste piramide u Sakari. Te su građevine i njihovi tekstovi nastali negdje oko 2400. godine pr.

At the beginning of the third millennium the idea of pyramids was born in Egyptian architecture. It is believed that the first pyramid was the one of pharaoh Djoser at Saqqara, not far from Cairo, and it was followed by a few more in Dahshur and Meidum. After that a major project followed including the construction of three large pyramids at Giza. Although many people believe that pyramids were not meant exclusively as pharaonic tombs, it is by all means under the influence of those rulers, who considered their accession to the sky as a continuation of their ruling after death, that pyramids were built. These constructions are an expression of the building capacity and technological progress of the overall society in the pharaonic state, as well as of the spirit that cherished eternity depicted on stone. Three large pyramids do not provide us with much insight into the Egyptian cognition and theories on the after-life. There are in fact no engraved texts either on, or inside them. However, the situation is significantly different when small pyramids of the 5th and 6th dynasties are considered. They are in fact real treasuries of our cognitions on eschatology, theology and the life of

kr.⁷, oni opisuju uzlazak na nebo i nadvladavanje sila zla što je po Egipćanima bilo od vitalnog značaja za nastavak života u vidljivom svijetu. Magijske bajalice i izričaji koji čine te tekstove faraonu su trebali omogućiti izlazak vladara i njihovih mrtvih tijela, potom sarkofaga i grobnice, te konačno uzlazak na nebo. Stoga *Tekstovi piramida* (u narednim referencama skraćeno *TP*) teku od pogrebne komore sve do izlaznih vrata. Kako smo već objasnili, *ka* i *ba*, preživljavaju smrt tijela i odvajaju se od njega. Ali faraonska duša nije poput one običnih ljudi. Prolazak faraonske duše kroz svijet mrtvih je mitsko djelo. To je herojski podvig u kojem duša vladara sudjeluje u borbi dobra i zla na strani sunca u borbi protiv sila mraka. Vladareva borba protiv sila kaosa odredit će sudbinu zemlje, stoga njegov ukop ima iznimnu važnost. To je ono o čemu *Tekstovi piramida* govore.

Nakon što je izrekao molitve bogovima i izričaje pročišćenja Unis – prvi faraon kojem su ovi spjevovi na zidovima piramide bili posve-

⁷ Najraniji je primjer pronađen u piramidi faraona Unisa. Nakon Unisa, tekstovi su uklesani u piramide faraona 6. dinastije Teija, Pepija i Merenrea. *Tekstove Piramida* prvi je otkrio 1881. godine slavni francuski egiptolog Gaston Maspero, nakon što godinama nitko nije pokazivao interes za ruševine malih piramida u Sakari. Prijevod kompletnog opusa ovih tekstova objavili su: R. O. Faulkner, K. H. Sethe i S. A. B. Mercer.

the soul of the Egyptians. *The Pyramid Texts* were found in small pyramids located close to the Step Pyramid of Djoser in Saqqara. Those buildings and their texts originated sometime around 2400 BC.⁷ They describe the accession to the heavens and overcoming the forces of evil, which the Egyptians considered to be of vital importance for continuing life in the visible world. Magical spells and utterances, contained in those texts, were meant to allow pharaohs to leave their dead bodies, the sarcophagi and the tombs, and finally allow the rulers to ascend to the heavens. *The Pyramid Texts* (hereinafter shortened to *PT*) stretch from the funerary chamber up to the exit door. As already explained, *ka* and *ba* survived the death of the body and were separated from it. However, the soul of the pharaoh was not like the one of common people. The passage of the pharaoh's soul through the world of the dead was considered a mythical act. It was a heroic accomplishment in which the soul of the ruler participated in the strug-

⁷ The oldest exemplar was found in the pyramid of pharaoh Unis. After Unis, texts were carved in the pyramids of the pharaohs of the 6th dynasty, such as Tei, Pepi and Merenre. *The Pyramid Texts* were first discovered by the famous French egiptologist Gaston Maspero in 1881, after many years in which nobody expressed any interest in the ruins of the small pyramids in Saqqara. The translations of the entire opus of those texts were made by R. O. Faulkner, K. H. Sethe i S. A. B. Mercer.



TRI VELIKE PIRAMIDE
na Platou Giza
THREE LARGE PYRAMIDS
on the Giza Plateau



PIRAMIDA TETIJA u Sakari / PYRAMID OF TETI in Saqqara

ćeni - osvješćuje svoj *ka*. Tekst izgovara svećenik koji pri tome pali tamjan i obavlja libacije za koje se u tekstovima također nalaze upute. Pretpostavlja se da je već i u to vrijeme mumificiranje bilo najvažnije za nastavak života duše. Naime, duša koja ne bi imala *akh* ne bi se mogla kretati u nebeskom svijetu *Duat*. No ostaci mumija iz tog razdoblja nisu pronađeni. Dio teksta iz Unisove piramide očito govori i o postupku mumificiranja:

*O Unise, ruka tvoga ka je pred tobom
O Unise, ruka tvoga ka je iza tebe
O Unise, stopalo tvoga ka je ispred tebe
O Unise, stopalo tvoga ka je iza tebe
O Ozirise⁸ Unise, dajem ti Horusovo oko⁹
Kako bi se tvoje lice njime okitilo*

⁸ Umrla osoba, u ovom slučaju faraon Unis, poistovjećuje se s bogom mrtvih Ozirisom.

⁹ Horusovo oko (egip. *uđat*) jedan je od glavnih simbola kreativne i regeneracijske moći u Egiptu. Riječ je o sunčevom oku iz kojeg je nastao život i ljudska bića. *Uđat* se povezuje i s *iaretom* (gr. *ureus*) – glavom kobre koja se podiže, što je povezano sa simbolikom uskrnuća. U ovom ritualu prinosio amulet oka *uđat*.

gle of good and evil on the side of the sun in the struggle against the forces of the dark. The ruler's fight against the forces of chaos was to determine the world's destiny and his burial was therefore of exceptional importance. This is what is written in the *Pyramid Texts*.

After pronouncing the prayers to the gods and purification spells, Unis – the first pharaoh to whom those poems on pyramid walls were dedicated, awakes his *ka*. The text is pronounced by a priest who lightens the incense and performs libations for which the instructions are also found in the texts. Already at that time mummification was probably considered most important for the soul to continue its life. In fact, a soul that did not have an *akh* would not be able to move into the celestial world of the *Duat*. Remains of mummies of that period have still not been found. Part of the poem from the pyramid of Unas obviously deals with the mummification procedure:

*Neka ovaj parfem Horusovog oka bude raspršen po tebi
Polijevanje ljevanice po stopalima
Ovo je tvoje pročišćenje Ozirise
Ovo je tvoje pročišćenje o kralju Unise
Došao sam kako bih ti prinio Horusovo oko
kako bi tvoje srce bilo osvježeno njime
Donijeh ja njega pred tvoja stopala (TP, izričaj 25, 32)*

Nakon ovoga slijedi ritual otvaranja usta kojim duša Unisa dobiva moć govora u svijetu mrtvih. To je osobito važno jer od toga trenutka on magičnim izričajima sam krči put do oslobođenja.

*O Unise ja sam otvorio tvoju vilicu za tebe s alatkom od željeza bogova
O kralju Unise ja sam otvorio tvoja usta za tebe (TP, izričaj 25)*

Nakon otvaranja očiju i osvještavanja zuba i usta, Unisovo tijelo polijevalo se sa sedam vrsta ulja. Nakon toga bili su posvećeni laneni povoji kojima će tijelo biti omotano. Nakon toga ponavljaju se libacije i slijedi priprema stola sa žrtvama, i vokacija kralja da se probudi i ustane iz lijesa. Obnavlja se njegov dah kroz nosnice i kralj potpuno oživljava kao duša.

Nakon mnogih libacija i molitvi za oživljavanje duše svećenik ispraća Unisa koji kroči u Duat. Pred njim je plameno jezero.

Govori svećenik:

*O kralju Unise
Ti si otišao mrtav
Ti si otišao živ
Zasjedni na prijestolje Ozirisovo
Tvoja palica je u tvojim rukama
Kako bi mogao vladati živima
Tvoj štap u obliku lotosa je tvojim rukama
Kako bi mogao naređivati onima čija su mjesta skrivena. (TP, izričaj 137)*

Govori svećenik:

*O Unise, čuvaj se
Pred tobom je ognjeno jezero
Ponoviti četiri puta
Glasnici tvojeg ka dolaze k tebi
Glasini tvog oca dolaze k tebi govoreći:*

*O King Unas, the arm of your Ka is before You!
O King Unas, the arm of your Ka is behind You!
O King Unas, the foot of your Ka is before You!
O King Unas, the foot of your Ka is behind You!
O Osiris⁸ King Unas, I have given You the Eye of Horus⁹!
May your face be adorned with it !
May the perfume of the Eye of Horus diffuse over You!
Pouring of libation under the feet
This is your libation, Osiris.
This is your libation, O King Unas.
I have come and I bring You the Eye of Horus, that your heart may be refreshed with it. I bring it to You under your feet. (TP, Spell 25, 32)*

After that, the opening of the mouth ceremony takes place, whereby the soul of Unas is conveyed the power of speech in the world of the dead. This is of particular importance since it is from that very moment that Unas with magical spells blazes the trail towards freedom.

*O Osiris King Unas, I split open your mouth for You.
by divine iron of Upper Egypt (PT, Spell 25)*

Once the eyes were opened and the teeth and mouth awoke, seven types of oils were poured on Unas' body, then the linen strips used for wrapping the body were consecrated, after that libations were repeated, followed by the preparation of the table with the sacrifices and the invoking of the king to wake up and walk out of the coffin. His breath was renewed through the nostrils and the king is fully revived as a soul.

After numerous libations and prayers for reviving the soul, the priest accompanies Unas into Duat. A lake of fire is in front of him.

⁸ The deceased person, in this case pharaoh Unis, identifies himself with the god of the dead Osiris.

⁹ The Eye of Horus (Egip. *Uadjet*) is one of the main symbols of the creative and regenerative power in Egypt. It is the eye of the sun from which life and living beings originate. *Uadjet* is also associated with iaret (gr. *uraeus*) – from the image of a cobra rising up, which is related to the symbolism of resurrection. In this ritual the amulet of the eye *Uadjet* was offered.

Idi za Suncem i pročisti se jer tvoje kosti potječu od sokolskih božanstava

koja su na nebu

Neka tvoje boravište bude uz boga

Neka ti napustiš svoju kuću i uzdigneš se do Sunca.

Neka padne u ropstvo svatko tko bude govorio protiv kralja Unisa

Uzdigni se, jer Geb je ponizio tvoje protivnike u gradu "One koja je noseća"

kako bi potonuli u svojoj iscrpljenosti

A ti ćeš se okupati u svježini vode sa zvijezda

Ukrat ćeš se na sunčanu barku preko čeličnih struna

na ramenima Horusa zvanog "Onaj tko je u Sokarovoj¹⁰ barci"

Narod Sunca¹¹ uzvikivat će tvoje ime

Kad te "oni koji ne znaju za umor"¹² uzdignu sa zemlje

Uzdigni se do mjesta na kojem je tvoj otac, do mjesta na kojem je Geb

Koji će ti podariti ono što je na obrvi Horusa kako bi imao akh na tom mjestu

Preuzmi kontrolu nad tim mjestom i bit ćeš tamo na čelu Zapadnjaka¹³ (TP, izričaj 137-138)

Nakon toga kralj dolazi na nebo i hrani se žrtvama bogova. U zoru blijedi zajedno s ostalim zvijezdama koje se stapaju s Orionom. Danju se pridružuje Suncu i nastavlja kružiti nebom na nebeskoj barci. Prema jednoj verziji koja se naziva "himnom kanibala" uzletjevši na nebo faraon proždire duše ljudi i bogova te postaje najmoćnije biće i apsolutni vladar neba i svijeta mrtvih Duata.

Kralj se uzdiže na nebo

Nebo je pomračeno

Potamnjele su zvijezde

Tresu se nebeska prostranstva

Drhte kosti Akera

Planete su zastale

Sve je stalo ugledavši kralja

¹⁰ Sokar – Bog u liku sokola. Jedno od božanstava Duata.

¹¹ Narod *henemet* – prevodi se kao "sunčani ljudi" ili "narod Sunca". Točno značenje nije sasvim objašnjeno.

¹² Zvijezde stajačice.

¹³ Zapadnjaci – "ljudi su na zapadu" su oni koji su u kraljevstvu mrtvih.

By the priest:

O King Unas !

You have gone away dead

You have gone away alive

Sit upon the throne of Osiris.

Your Power-sceptre in your hand,

that You may give orders to the living.

Your Lotus-bud sceptre in your hand,

that You may give orders to those whose seats are hidden. (PT, Spell 137)

By the priest:

O King Unas, beware of the Lake (of Fire) !

-to say the words four times-

The messengers of your Ka come for You.

The messengers of your father come for You.

The messengers of Re come for You, (saying) :

"Go after your Sun and cleanse yourself, for your bones are those of the divine falcon-goddesses who are in the sky.

May You be beside the god.

May You leave your house and ascend to your son."

May You fetter anyone who shall speak evilly against the name of King Unas

Go up, for Geb has committed him to a low estate in the town of "The pregnant one", so that he may flee and sink down weary.

But You shall bathe in the cool water of the stars.

You shall board the Sunboat upon ropes of iron, on the shoulders of Horus in his name of "Him who is in Sokar's boat"

The Sun-folk will cry out your name once the Imperishable Stars have raised You aloft.

Ascend to the place where your father is, to the place where Geb is, that he will give You that which is on the brow of Horus, so that You shall come an Akh thereby, take control thereby and that You shall be at the head of the Westerners thereby. (PT,137-138)

After that, the king comes into the sky and eats the offerings sacrificed to the gods, at dawn he fades away together with all other stars that are united with Orion. By day he joins the Sun and continues circulating in the sky in the celestial ship. According to one version named "cannibal's hymn" after

Uzdiže se ba

*Njegovi bogovi su iznad njega
Njegov ureus je na njegovom čelu
Zmija koja vodi kralja je na njegovom čelu
Ba¹⁴ kojega vidi je svijetla vatra
Kraljev vrat je na njegovom trupu
Kralj je bik neba
Snažno tuče srce onoga koji boravi u svim bogovima
On jede iznutrice onih koji dolaze tijela punih magije
S otoka vatre*

*Kralj je gospodar žrtvi
On veže konopcem
On je taj koji sebe opskrbljuje žrtvama
Kralj se hrani ljudima, a živi od bogova
On je gospodar glasnika što nose poruke
On ih užetom veže za rogove
Zmija podignute glave je ta koja ih odbija od njega
Čerut¹⁵ ih ubija za njega
Khonsu siječe žrtve za njega
Vadi za njega ono što je u njihovim tijelima*

*Kralj se ponovno uzdigao na nebo
On je okrunjen kao gospodar horizonta
On je slomio kraljeznice,
I uzeo srca bogova
Pojeo je crvenu krunu,
progutao je Zelenu
On se hrani plućima mudrih
Miran je on jer živi od njihovih srca i magije
On odbija jesti one što su u Crvenoj kruni
Ali uživa kad njihova magija dospije u njegovo tijelo
Neka mu se ne oduzmu njegovi akhuovi
On je progutao znanje svih bogova
On beskonačno živi u vječnosti
Njegova uzvišenost čini što mu se sviđa
Ne čini ono što mu se ne sviđa
On je zauvijek na horizontu
Gle, njihove duše su u njegovom tijelu,
Akhuovi njihovi pripadaju njemu
Njemu pripada više božanskih žrtava
Njemu se kuha više od njihovih kostiju*

¹⁴ Viši, duhovni oblik duše u obliku ptice. Za razliku od *ka*, *ba* nakon smrti odlazi u nebo.

¹⁵ Jedan od demona iz Duata.

ascending to the sky, the pharaoh devours the souls of men and gods becoming the most powerful creature and the absolute ruler of the sky and of Duat - the world of the dead.

*The King Ascends to the sky
The sky overcast.
The stars darken.
The celestial vaults stagger.
The bones of Aker¹⁰ tremble.
The planets are stilled against them,
at seeing King rise as a Ba.*

*A god who lives on his fathers and feeds on his mothers.
King Unas is Lord of Wisdom whose mother knows not his name.
The glory of King is in the sky, his might is in the horizon.
Like his father, Atum, his begetter.
Though his son, King is mightier than he.
The Kas of King are behind him.
His hemsut forces are under his feet.
His gods are over him.
His Uraeus-serpents are on his brow.
The guiding-serpent of King Unas is on his forehead :
she who sees the Ba¹¹ (of the enemy as) good for burning.
The neck of King is on his trunk.
King is the Bull of the Sky,
who shatters at will,
who lives on the being of every god,
who eats their entrails,
even of those who come with their bodies full of magic from the Island of Fire.
King is The Lord of Offerings,¹²
who knots the cord,
and who himself prepares his meal.
King is he who eats men and lives on gods,
Lord of Porters, who dispatches written messages.
It is "Serpent Raised-head", who guards them for him*

¹⁰ The god of Earth.

¹¹ A higher spiritual shape of the soul in the form of a bird. Unlike *ka*, after death *ba* ascends to the sky.

¹² A deity of Tebes.

Gle, njihove duše, njihove sjene i njihovi likovi
su ispred kralja

Kralj je taj koji se uzdiže i traje

Zlotvori nemaju moći da unište

Vječno mjesto njegovog zadovoljstva na ovoj
zemlji (TP, izričaji 273-274)

Uzlazak vladara na nebo glavni je motiv
Tekstova piramida. On se ponavlja u niz va-
rijanti. U nekima faraon se pretvara u pticu
i uzlijeće prema suncu napuštajući iza sebe
svijet običnih ljudi.

Moje mjesto je pored tebe, o Ra

Ja ga neću prepustiti nikome

Uzdići ću se k tebi u nebo, o Ra

Moje lice je lice sokola

Moja krila su krila patke

Moje pandže su pandže onoga s planine Kerstes

Među ljudima na zemlji nema riječi protiv
mene

Nema protiv mene optužbe među bogovima na
nebu

Jer ja sam poništio sve riječi protiv mene

Uništio sam ih kako bih se uspeo na nebo

Upuaut je učinio da uzletim na nebo među svo-
ju božansku braću

Rukama se služim poput guske

Krilima mašem kao sokol

Letač leti

O ljudi, ja letim

Odlazim od vas (TP, izričaj 303)¹⁶

Iz svega što nam govore ovi zagonetni teksto-
vi puni mitskih slika može se zaključiti da je
mumifikacija i vječni život u vrijeme gradnje
piramida bila privilegija vladara. Ne raspo-
ložemo nikakvim dokazima da su se ti postu-
pci i obredi u vrijeme gradnje prvih piramida
obavljali i nad drugim ljudima. Poznato je da
su se dvorjani i osobe bliske vladarima poka-
pali u neposrednoj blizini piramida. Možda
je sama blizina vladarskih grobnica imala
određenog utjecaja na njihov zagrobni život.
No što se mumificiranja tiče iz spomenutog
razdoblja pronađeno je tek nekoliko ostata-
ka, dijelova tijela. Sve piramide i grobnice iz
starog kraljevstva bile su devastirane još u
starom vijeku.

¹⁶ Prijevodi prema: R. O. Faulkner, *The Ancient Egyptian Pyramid Texts*. 1969.

It is Khons¹³ who slew the lords

Who strangles them for King

And extracts for him what is in their bodies

King Unas has risen again in the sky.

He is crowned as Lord of the Horizon.

He has smashed the back-bones,

and has seized the hearts of the gods.

He has eaten the Red Crown.

He has swallowed the Green One¹⁴

The King feeds on the lungs of the wise.

And likes to live on hearts and their magic.

The King revolts against licking the Coils of the
Red Crown.

But delights to have their magic in his belly.

The dignities¹⁵ of the King will not be taken
away from him.

For he has swallowed the knowledge of every
god.

The lifetime of the King is eternal repetition.

His limit is everlastingness.

In this his dignity of :

“If-he-likes-he-does. If-he-dislikes-he-does-
not.”

He who is at the limits of the horizon forever
and ever.

Lo, their Bas is in the belly of the King.

Their Akhs are in the possession of the King,
as the surplus of his meal out of the gods.

Which is cooked for the King from their bones.

Lo, their Ba is in the possession of the King.

Their shadows are removed from their owners,
while the King is this one who ever rises and
lasting lasts.

The evildoers of ill deeds have no power to de-
stroy, the chosen seat of King Unas, among the
living in this land.

Forever and ever. (PT, 273-274)

The accession of the king to the sky is the
main motive in the *Pyramid Texts*. It is re-
peated in a line of variations. In some of

¹³ One of the demons of Duat.

¹⁴ These are the symbols of Lower Egypt. The red crown was worn by the rulers of Lower – northern Egypt before unification. Later on, after Narmer's victory over Delta towns and the constitution of a single unified state, pharaohs wore a double crown made of a red and a white one. “The Green One” refers to the snake-headed goddess Uadjet, the ruler from Delta.

¹⁵ Light creatures, spirits



them, the pharaoh is transformed into a bird and flies towards the sun leaving behind the world of common people.

The king ascends towards heaven near you, Re, while his face (is like that of) hawks, his wings (are like those) of apd-geese, his talons (like) the fangs of He-of-the-Dju-ef-nome.

There is no word against Unas on earth among men,

there is no crime of him in heaven among gods.

Unas has done away with the word against him,

Unas has annulled it in order to rise towards heaven.

Upuaut has let Unas fly to heaven amongst his brothers, the gods.

Unas has moved his arms like a goose; he has beaten his wing like a kite.

He flies up, he who flies up, O men!

Unas flies up away from you!" (PT, 303)¹⁶

What can be inferred from those enigmatic texts full of mythical pictures is the fact that at the time of the building of the pyramids, mummification and eternal life were a privilege of rulers. There is no evidence whatsoever that would support the thesis that at the time of the building of the first pyramids these procedures and rituals were performed also on other people. What we do know however is that noblemen and people who were close to the rulers were buried in the immediate vicinity of pyramids. Maybe, the very vicinity to the rulers' tombs had a certain impact on their afterlife. Still, as far as mummification from the said period is concerned, only few remains of body parts have been found. All pyramids and tombs of the Old Kingdom were devastated as early as in the Ancient Era.

¹⁶ Translations based on: R. O. Faulkner, *The Ancient Egyptian Pyramid Texts*. 1969.

Demokratizacija vječnog života

Democratisation of Eternal Life

Samo su vladari mogli mobilizirati narod kako bi gradili piramide koje su im jamčile ulazak u vječni život. No padom Starog kraljevstva pada i sama moć vladara. Lokalni moćnici počinju se ponašati poput vladara te, između ostalog, i sami teže za vječnim životom svojih duša. Još se od doba Keopsa plemići sahranjuju u *mastabama*¹⁷ u neposrednoj blizini piramida kako bi sudjelovali u njihovoj besmrtnosti. Tako se pomalo razvija svojevrsna “demokratizacija” vječnog života koja se može detektirati od Srednjeg kraljevstva na dalje. Svaki Egipćanin¹⁸ želi biti mumificiran i uz obrede pohranjen u grobnicu s ciljem postizanja oslobođenja duše po uzoru na drevne vladare. Tekstovi nekad ispisivani na zidove piramida i *mastaba* tada se počinju klesati na kamene i oslikavati na stijenke drvenih sarkofaga. Takozvani *Tekstovi sarkofaga* i konačno *Knjige mrtvih* koje se pišu na papirusima, neka su vrsta sažetka *Tekstova piramida*. Kad su u pogrebne običaje uvedene *Knjige mrtvih* vječni život je za svakog građanina bio nadohvat ruke. Trebalo je naručiti papirus s neko-

¹⁷ *Mastaba* (arap. *stuba*) – kamena grobnica kosih zidova s dubokim oknom koje se spušta u podzemne prostorije.

¹⁸ Dakako, pri ovome treba izuzeti seljake-zemljoradnike koji su vjerojatno bili sahranjivani u najskromnijim mogućim uvjetima.

Only kings could have mobilised the people to build pyramids that allowed entrance to eternal life. However, with the fall of the Old Kingdom also the power of the kings was lost. Local men of power started behaving like kings streaming, among other things, towards eternal life for their souls. Since the period of Keops, noblemen were buried in *mastabas*¹⁷ in the immediate vicinity of pyramids in order to participate in their immortality. It is in that way that a certain “democratisation” of eternal life took place that can be identified since the period of the Middle Kingdom. Every single Egyptian¹⁸ wished to be mummified and buried in a tomb with all the rituals in order to attain liberation of the soul following the model of ancient rulers. The texts that used to be written on the walls of pyramids and *mastabas*, started being carved onto stone and painted on the panels of wooden sarcophagi. The so-called *Coffin Texts* and finally the *Books of the Dead* that were written on papyri are a kind of summary of the *Pyramid Texts*. Once the *Books of the Dead* had been introduced into funerary rituals, eternal life was within arm's reach of every citizen. It

¹⁷ *Mastaba* (arap. *stuba*) – stone tomb with oblique walls and deep reaching underground premises.

¹⁸ Naturally, farmers should be excluded from that category as they probably had very modest burials.

liko odabranih poglavlja i položiti ga u grobnicu kako bi ga umrla osoba čije je ime bilo upisano u bajalice i izričaje koristila poput vodiča. Svećenici-čitači su pri mumificiranju i pogrebu izgovarali te magijske tekstove zazivajući njihovu pretvorbu u Ozirisa, šaljući duše na putovanje sunčanom barkom preko neba. Tako je vječnost duše bila osigurana.

Zamisao o izradi entiteta zvanog *akh* donekle je objašnjena u 17. poglavlju *Knjige mrtvih*. Ono se naziva *Početak inkantacija i rituala za izlazak svjetlećeg tijela iz grobnice, odlazak u prekrasni Amenti i postojanje u nazočnosti Ozirisa*¹⁹.

¹⁹ Prijevod: I. Uranić, *Stari Egipat*. Zagreb, 2002. 243-247.

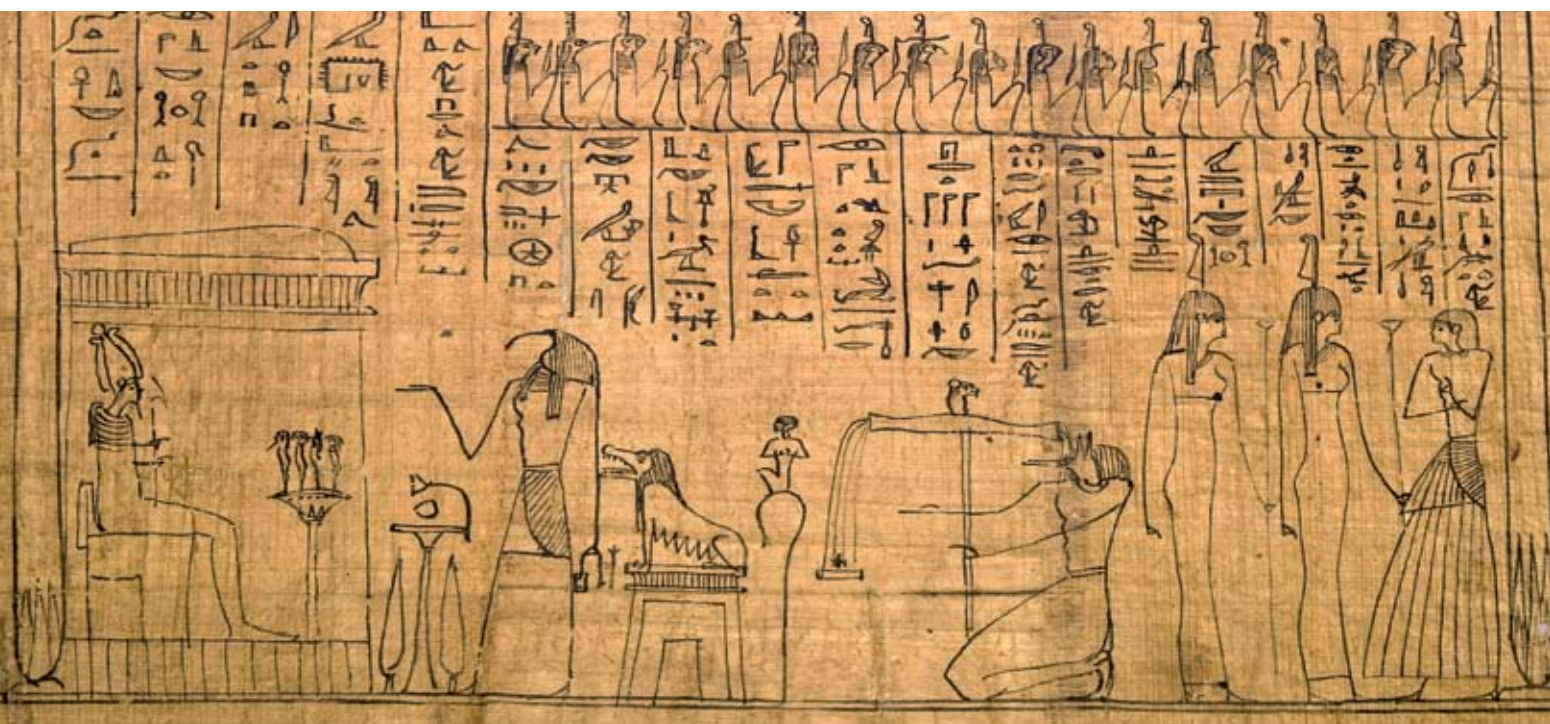VAGANJE SRCA , Papirus Zagreb 603 /

WEIGHING OF THE HEART, Papyrus Zagreb 603

was only necessary to order papyri with a few selected chapters and place them into the tomb so that the deceased, whose name was contained in the spells and utterances, could use it as a kind of guidebook to the afterlife. During the mummification process and the funeral, lector-priests pronounced magical texts invoking the deceased's transformation into Osiris and sending the soul on a journey by the solar boat across the sky. It was in that way that eternity was guaranteed to the soul.

The notion of the creation of an entity called the *akh* is to a certain extent explained in Chapter 17 of the *Book of the Dead*. It is called *The beginning of incantations and rituals for the coming out of the light body from the tomb, going to the beautiful Amenti and the existence in the presence of Osiris*¹⁹.

¹⁹ Naville, *Todtenbuch*, Bd. I., XXVII.



Štoviše, u početnim stihovima teksta se spominje mogućnost da se *akh* izradi još za života. Nije poznato što to točno znači, ali očito je postojalo vjerovanje da je svjetleće tijelo neka vrst sposobnosti ili moći, koja se na neki način “nadoknađuje” mumificiranjem.

Moreover, in the initial verses of the texts the possibility of creating the *akh* already during one's lifetime is mentioned. We are not sure about the exact meaning, but there was obviously a belief that the light body is a type of skill or power that can be “made up for” by mummification in some way.

Hieroglyphic text at the top of the panel, including a cartouche.



Horizontal line of hieroglyphs separating the central illustration from the text columns below.

Small horizontal line of hieroglyphs above the first column of text.

Vertical column of hieroglyphs on the far left side of the panel.

Vertical column of hieroglyphs, second from the left.

Vertical column of hieroglyphs, third from the left.

Vertical column of hieroglyphs, fourth from the left.

Vertical column of hieroglyphs, fifth from the left.

Vertical column of hieroglyphs on the far right side of the panel.

Dakle, u tom poglavlju oživljena duša *ba* nakon uspješnog mumificiranja svojim svjetlećim tijelom (*akh*) izlazi iz grobnice kroz tzv. lažna vrata uklesana u zid. Tekst stalno naglašava kako je duša ponovno oživljena. Duša se poistovjećuje sa svemogućim stvoriteljem Atumom, bogom mrtvih Ozirisom i drugim božanstvima. Umrli izgovara mnogobrojna sveta imena kako bi zazvao njihovu snagu. Spominje mitske lokacije i sakralne radnje bogova te njihova imena kako bi pokazao svoje znanje. Potom, umrla osoba uzima na sebe razne zasluge iz mitskih događanja, poput spašavanja Horusovog oka koje mu je u okršaju za prevlast izbio Set. To oko je osobito svet predmet jer se povezuje sa Suncem i obnovom sveukupnog života. Na kraju poglavlja umrli zaziva imena četiri Horusova sina koji čuvaju organe izvađene iz mumije i pohranjene u kanope.

Ove složene predodžbe pokazuju nam koliko je maštovito i detaljno bio zamišljen svijet u kojem se odvija zagrobni život. Mitologija vječnog života bila je uglavnom povlastica viših slojeva. Obredi i svečanosti oko ukopa, što uključuje i pisanje samih pogrebnih tekstova, bili su posao svećenstva. U biti, svećenike možemo smatrati izvorom ukupne eshatologije i mitologije zagrobnog života, što su izrasli iz njihove imaginacije. Također, čini se da su i sami faraoni katkad unosili određene promjene u predočavanju zagrobnog života, što se može zaključiti po promjenama ikonografije njihovih grobnica. Od Novog kraljevstva raskošne ukope i kvalitetnu mumifikaciju mogli su si priuštiti mnogobrojni plemići, svećenici, ali i pisari, i obrtnici, koji su naseljavali egipatske gradove.

In this chapter, after a successful mummification, the reanimated soul *ba* leaves the tomb together with its light body (*akh*) through the so-called false door carved on the wall. The text keeps pointing out the fact that the soul is reanimated again. The soul is equated with the almighty creator Atum, with Osiris, god of the dead, and with other deities. The deceased uttered numerous sacred names, in order to invoke their power, and mentioned mythical locations and sacred activities of the gods as well as their names in order to show their knowledge. Thereafter, the dead person took over various merits associated with mythical events, like the rescue of the eye of Horus that was snatched by Seth in their fight for power. That eye is a particularly sacred item since it is associated with the sun and the revival of the entire life. At the end of the chapter, the deceased invoked the names of the four sons of Horus, who look after the organs taken out of the mummy and stored in canopic jars.

Those complex imageries show the fanciful and detailed manner in which the world of the afterlife was conceived. The mythology of eternal life was mostly a privilege of higher layers. Burial rituals and celebrations, which included the writing of the very funerary texts, were assigned to the clergy. As a matter of fact, priests may be considered as the source of the overall eschatology and mythology of the afterlife that originated from their imagination. Sometimes however, pharaohs introduced certain changes in presenting the afterlife, as can be inferred from the changes in the iconography of their tombs. Since the period of the New Kingdom, numerous noblemen, priests but also scribes and artisans living in Egypt could afford luxurious burials and high-quality mummification.

LAŽNA VRATA KHENUA (Sakara)

Uklesana u zidu grobnice bila su prolaz za dušu


THE FALSE WALL OF KHENU (Saqqara)

Carved on the tomb's wall was meant as a passage for the soul


Mumificiranje

Mummification

Riječ mumija je izvedena iz srednjovjekovnog latinskog izraza *mumia*, koji je posuđen od perzijske riječi *mūm* koja znači “bitumen” za kojeg se mislilo da se koristio pri balzamiranju. Izvorni egipatski izraz za mumiju

je *sah*  što znači “aktivirati *akh*” - nevidljivi prijenosnik duše. Mumija je sasušeno ljudsko ili životinjsko tijelo obrađeno i konzervirano postupkom koji nazivamo “mumificiranjem” ili “mumifikacijom”. Egipćani su postupke mumificiranja razvijali i primjenjivali tijekom tri tisuće godina trajanja njihove civilizacije. Za njih je taj proces bio izravno povezan s njihovim mitsko-eschatološkim pogledom na svijet. Bio je to obredni postupak kojim se duši mrtvoga omogućavao vječni život u nevidljivom svijetu Duatu, kakav je opisan u egipatskim tekstovima. Čovjek čije tijelo ne bi bilo mumificirano bio bi osuđen na takozvanu “drugu smrt” i lišen života poslije smrti. Najstarija sasušena ljudska tijela u Egiptu potječu iz preddinastijskih kultura. U tom su se razdoblju tijela mrtvih sahranjivala u zgrčenom položaju uz darove poput zavjetnih posuda. Ova su tijela bila mumificirana prirodno – uslijed suhoće pustinjskih uvjeta.

The word “mummy” derives from the middle age Latin expression *mumia* which is a borrowing from the Persian word *mūm* meaning “bitumen” that was believed to have been used in the embalming process. The original Egyptian expression for a mummy was *sakh*

 which meant “to activate the *akh*” – the invisible carrier of the soul. A mummy is a desiccated body, either human or animal, prepared and preserved by means of the process called “mummification” or “mummifying”. Egyptians developed and implemented mummification processes over three thousand years throughout the duration of their civilisation. For them, this process was directly connected to their mythical-eschatological view of the world. It was a ritual procedure whereby the soul of the deceased was granted eternal life in the invisible world of the Duat, as it was described in Egyptian texts. A person whose body was not mummified would be destined to dying “a second time” and would be deprived of life after death. The oldest human desiccated bodies in Egypt originate from the Predynastic Period. In that period, the bodies of the dead were

Malo je dokaza koji upućuju na same početke običaja mumificiranja. No podaci kojima raspolažemo ukazuju da je mumificiranje bilo poznato već za prvih dinastija, dakle, na početku trećeg tisućljeća stare ere. U grobnici kralja Đera iz 1. dinastije (početkom 3. tisućljeća pr. Kr.) pronađena je mumificirana ženska ruka okićena narukvicom, kakva je mogla pripadati kraljici. Mumije faraona koji su gradili piramide Đosera, Keopsa, Kefrena i Mikerina nestale su. Većina mumija koje se čuvaju u muzejima diljem svijeta potječu iz Novog kraljevstva i kasnog te ptolemejskog razdoblja. Dakle, otprilike iz razdoblja između 1550. i 30. pr. Kr. U svakom slučaju, mumificiranje je dostiglo svoj tehnološki vrhunac za Novog kraljevstva (1550.-1069. pr. Kr.).

AKH prijenosnik duše
AKH carrier of the soul



buried in a contracted position alongside the gifts like votive vessels. Those bodies were naturally mummified – as a consequence of dry desert conditions.

There is little evidence about the very beginnings of the mummification practice. Still, the data available show that mummification was already known at the time of the first dynasties, i.e. at the beginning of the third millennium of the Ancient era. In the tomb of Djer of the first dynasty (the beginning of the 3rd millennium BC), a mummified female arm was found adorned with a bracelet that could have belonged to a queen. The mummies of pharaohs who built the pyramids of Djoser, Keops, Kefren and Mikerin have disappeared. Most mummies stored in museums all around the world originate around the period of the New Kingdom, the Late Period and the Ptolemaic Period, i.e. from the period about between 1550 and 30 BC. Mummification as such reached its technological peak during the New Kingdom (1550-1069 BC).

BA se uzdiže iz mumije / BA elevating from the mummy



Glavni motiv pokušaja da se tijelo očuva mumificiranjem je mit o ubojstvu i uskrснуću mitskog kralja Ozirisa. Budući da je taj mitski kralj pobijedio smrt nakon što mu je zli bog Set raskomadao tijelo, onda je to moguće i ljudima. Isprva se to odnosilo samo na faraone, a kasnije na sve ljude. Vjerovanje u obnovu života i uskrснуće kod Egipćana povezani su i s kultom Sunca koje se svakog dana pri izlasku rađa, a na zalasku kao da umire. To ih je asociralo na život, smrt i obnovu života.

O tehnologiji samog postupka što su ga obavljali svećenici u "kućama ljepote" (eg. *per-nefer*) pisao je grčki putopisac Herodot. On je u svom djelu *Historie* (II. 86-91) naveo da je taj ritual trajao sedamdeset dana. No mumificiranje je moglo biti obavljeno na više načina, a njegovo je trajanje moglo varirati.

BRONČANA STATUA boga Ozirisa (Muzej Mimara)
BRONZE STATUE of God Osiris (Museum Mimara)



The major motif for trying to preserve the body by mummification was the Osiris myth, a myth concerning the murder and resurrection of the mythical king Osiris, who overcame death after his body had been torn into pieces by his evil brother Set. If Osiris resurrected, men could do the same. At first, this was possible only for pharaohs, but was later referred to all men. The belief of the Egyptians in the renewal of life and resurrection was connected to the cult of the Sun that is born every day at sunrise and seems to die at sunset. In fact, they associated the sun with life, death and the renewal of life.

It was the Greek historian Herodotus who wrote about the technology of the very procedure performed by priests in the "houses of beauty" (eg. *per-nefer*). In his work *Historie* (II. 86-91) he stated that that ritual lasted for seventy days. However, mummification could have been performed in many ways and its duration varied.

AMULET dva prsta
AMULET of two fingers



Odstranjivanje organa

Kad bi čovjek umro lokalni kraljev službenik objavio bi njegovu smrt u mjestu gdje je živio. Nakon toga mrtvo tijelo su svećenici prenijeli u *per-nefer*. Tijelo je bilo položeno na poseban kameni stol, lagano nakošen s otvorima za odvod tjelesnih tekućina. Stol je završavao poluokruglim spremnikom na nižoj strani. Tijelo bi prvo bilo oprano i depilirano.

Potom se trbušna šupljina prorezala s lijeve strane tijela kako bi se izvukli unutrašnji organi. Poželjno je bilo da se rez prostire od dijafragme do stidne kosti kako bi se osim probavnog trakta, slezene i jetra, mogli ukloniti i organi u prsnom košu: srce i pluća. Lijeva strana tijela, inače je bila povezana s istokom i bolešću. Istok je, osim toga, bio nepoželjna lokacija za dušu nakon smrti. Desna strana tijela je simbolično povezana sa zapadom (eg. *Amenti*) kamo se željelo otići jer se tamo nalazi Ozirisovo kraljevstvo. Čini se da je to razlog da se abdomen rezao s lijeve strane tijela. Također, ranu je kasnije trebalo zašiti i simbolično "izliječiti" kako je s Ozirisovim truplom postupio bog Anubis. U cilju magične komponente iscjeljenja uz mrtvacu se postavljao amulet dva prsta koji je predstavljao Anubisove iscjeljujuće prste. Rez je u većini slučajeva slijedio konfiguraciju trbuha ukoso prema dolje.

Organi su potom oprani mirisnim uljima i vodom, katkad odmah i umotani u trake, te nakon toga odloženi u četiri vaze, što su prema starim Grcima nazvane po nilskom rukavcu Kanopusu, kanopskim vazama. Ove su posude imale poklopce u oblicima četiriju božanstava, odnosno demona. Znatno delikatniji bio je postupak vađenja očiju i mozga instrumentima od bronce²⁰ kroz nosni otvor. Praktično mozak je trebalo oštrim predmetom pretvoriti u kašu, a potom kukama izvući komade i oprati šupljinu palminim vinom. Prave oči su se nadomještale staklenima. Smatra se da se izvlačenje mozga i očiju radilo prije otvaranja utrobe i vađenja organa.

²⁰ Zagrebačka istraživanja na tzv. "petoj mumiji" pokazala su da se to moglo obaviti i jednostavnim granama drveta ili trske.

Removal of Organs

When a man died, the local king's officer would announce his death in the place where he lived. After that, priests would take the dead body to the *per-nefer*. The body was placed onto a special stone table, lightly lopsided with openings for discharging body liquids. The table ended with a semi-circular container on the lower side. The body was then washed and epilated.

After that, the abdomen was cut from the left side of the body in order to remove the internal organs. It was advisable for the cut to stretch from the diaphragm to the pubic bone, so that apart from the digestive tract, milt and liver, also the organs of the chest could be removed: the heart and the lungs. The left side of the body was generally connected to the East and illness. Apart from that, the East was an undesirable location for the soul after death. The right side of the body was symbolically connected to the West (eg. *Amenti*) where everyone wanted to go to, since it was there that Osiris' Kingdom was located. This is apparently the reason why the abdomen was cut from the left side of the body. After that, the cut had to be protected and symbolically "healed" in line with the procedure applied on the body of Osiris by the god Anubis. With the aim of attaining the magical cure, an amulet of two fingers representing Anubis' healing fingers was placed alongside the dead. The cut followed mostly the configuration of the abdomen aslant and downwards.

Organs were washed with aromatic oils and water; sometimes they were immediately wrapped up in bandages and stored in four canopic jars. According to Ancient Greeks canopic jars were named after the Nile effluent Canopus. They had lids in the forms of four deities, i.e. demons. With the help of bronze instruments²⁰ a much more delicate procedure was performed for extracting the eyes and the brain through the nasal cavity. Practically, the brain was liquefied with

²⁰ Zagreb examinations of the so-called "fifth mummy" showed that this could have been performed by using simple branches of wood or cane.

Isušivanje i konzervacija

Tijelo se zatim dehidriralo pomoću natronske soli. Jednostavno je bilo zatrpano natronom. Nakon toga leš je bio sasušen i sličan uštavljenj životinjskoj koži. Tako isušeno tijelo nakon toga se polijevalo palminim vinom i raznim uljima, što ga je konačno konzerviralo. Zatim bi mumifikatori gumastim tvarima i smolama zatvarali rezove i oštećenja na tijelu. To bismo mogli nazvati kozmetičkom obradom tijela.

Zamatanje u trake i završni zahvati

Na kraju konzervirano i kozmetički obrađeno tijelo je bilo umotano u duge lanene trake. Između povoja su se postavljali amuleti nad kojima se pri tome izgovaralo posebne magijske bajalice kako bi ih se aktiviralo. Tijelo je odjeveno u lan i okićeno cvijećem i ogrlicama. Mumija se mogla prekriti mrežom valjičića od plave fajanse, zaštititi pozlaćenom kartonažom²¹, te položiti u drveni ili kameni, jednostruki ili višestruki sarkofag. To je, dakako, ovisilo o cijeni koju je mogao platiti naručitelj ukopa. Smolom, piljevinom i platom ispunjavala se praznina koja je u trupu nastala vađenjem organa. Kozmetika mumije uključivala je i manje operacije na ustima, koja su trebala biti očišćena kako bi umrli mogao izgovarati magične izričaje u svijetu mrtvih. Isto tako umjetne oči od stakla trebale su omogućiti vid umrlome u Duatu. Uređivali su se i prsti i nokti te pojačavali napršnjacima. Tutankhamonovi napršnjaci izrađeni su od zlata i bogato ukrašeni.

Kemijske tvari

Među najvažnijim tvarima i kemikalijama koje su služile za izradu mumija su voda, natron, alkohol, bitumen, smola, tamjan, mirodije, ulja, masti i lanene trake. Voda se rabila za ispiranje tijela nakon vađenja organa iz trupa. Ona je inače u svim egipatskim ritualima bila glavno sredstvo pročišćenja. Što se tiče natrona, on se u prirodi javlja kao

²¹ Obradena i obojena smjesa od slojeva blata i papyrusa ili platna kojom se štitila mumija.

a sharp tool, its pieces were then extracted with hooks and the cavity was washed with palm wine. Real eyes were replaced by glass ones. The extraction of the brain and eyes is believed to have taken place before the cutting of the abdomen and the removal of internal organs.

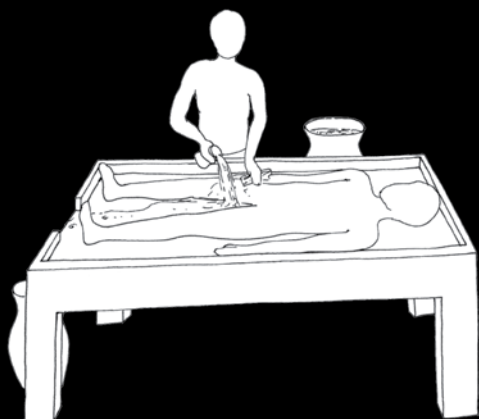
Desiccation and conservation

The body was then dehydrated with the help of natron salt. It was simply filled with natron. After that, the corpse was desiccated and was similar to tanned animal skin. Palm wine and various oils were then poured on the dried body finally preserving it. Rubbery substances and resins were then used by mummifiers to fill the cuts and damages present on the body, which could be defined as a cosmetic treatment of the body.

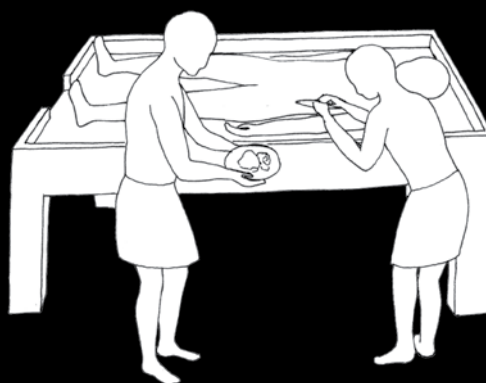
Wrapping up in bandages and final interventions

Finally, the preserved and cosmetically treated body was wrapped up in long linen strips. Amulets were placed between bandages on which special magical spells were pronounced so as to activate them. The body was clad in linen and was adorned with flowers and necklaces. The mummy could have been covered with a net of rolls of blue faience and protected with gilded cartonnage²¹, and placed into a wooden or stone, monopartite or polipartite sarcophagus. This obviously depended on the price the commissioner of the funeral was able to pay. The hole caused by the removal of the organs was packed with resin, sawdust and linen. The cosmetical treatment of the mummy involved also minor surgery of the mouth, which had to be cleaned so that the dead could pronounce magical spells in the world of the dead. Equally so, artificial eyes were supposed to allow the dead to see in the Duat. Also fingers and nails were treated and strengthened with finger protectors. For instance Tutankhamun's finger protectors are made of gold and are richly decorated.

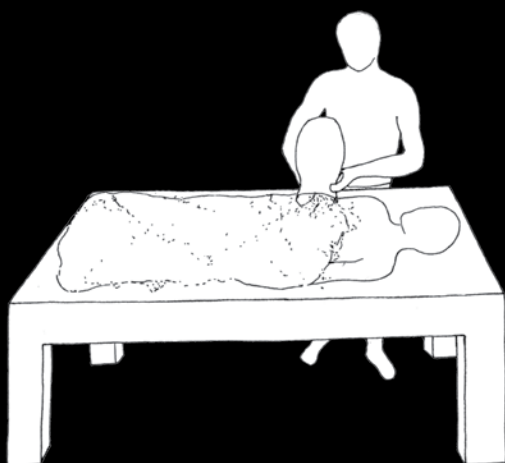
²¹ A processed and coloured blend of layers of mud, papyrus or linen used to protect mummies.



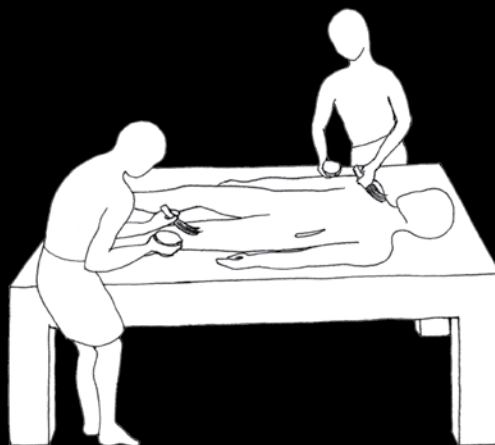pranje tijela
washing of the body



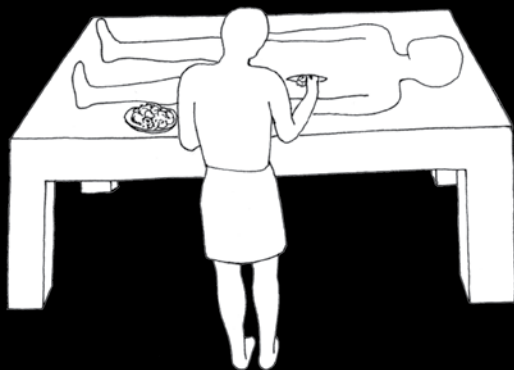otvaranje utrobe
i vađenje unutarnjih organa
cutting of the abdomen
and removal of internal organs



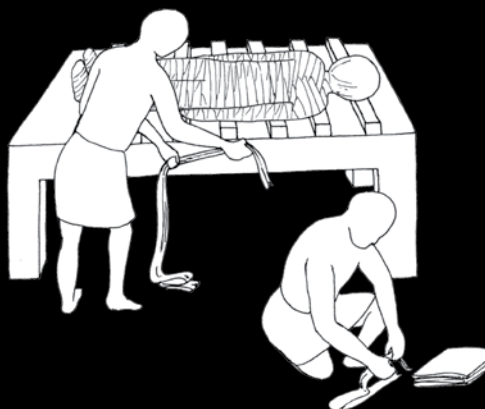
isušivanje i konzervacija tijela
pomoću natrona
desiccation and preservation
of the body with natron



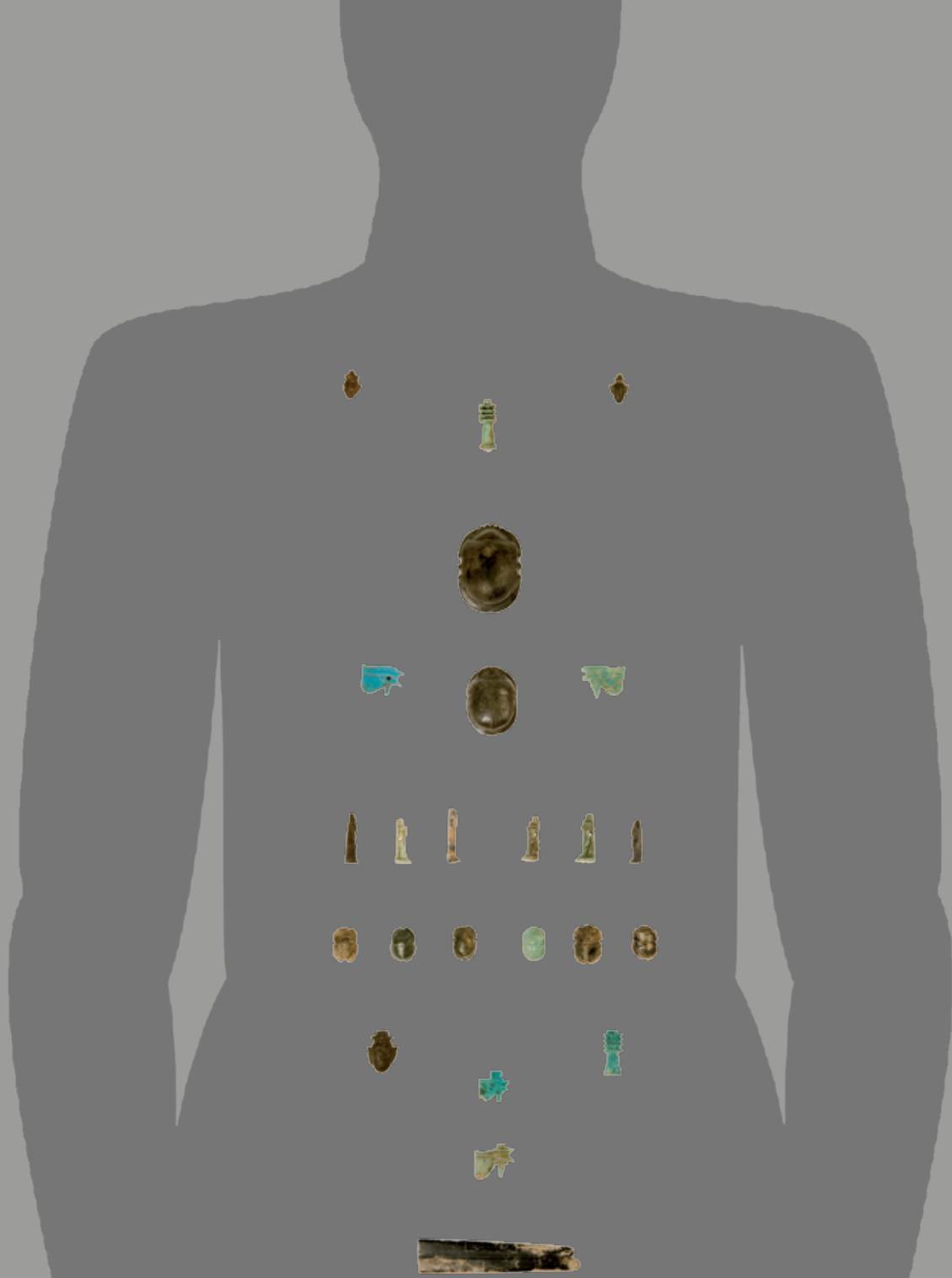
premazivanje balzamina i uljima
balsaming and oiling



kozmetički zahvati na tijelu
cosmetics



zamatanje mumije lanenim trakama
linen-wrapping of a mummy



RASPORED AMULETA NA DOVRŠENOJ MUMIJI

Amuleti nisu bili samo predmeti koji su se za života nosili u sklopu nekog nakita, već i zaštita mumije, odnosno njezine esencije zvane *akh*. Tijekom zamatanja povoja oko mumificiranog tijela svećenici su uzimali amulete, izgovarali nad njima bajalice, te ih potom postavljali na određena mjesta na mumiji. Time su dijelovi tijela i sposobnosti koje ima *akh* bile aktivirane.

THE ARRANGEMENT OF AMULETS ON A FINISHED MUMMY

Amulets were not only items carried together with pieces of jewellery during one's lifetime, but were also a protection for the mummy, i. e. of the mummy's essence called the *akh*. While wrapping up the mummified body priests would take the amulets and would pronounce spells returning and positioning them on certain places of the mummy. It was in that way that priests activated single parts of the body and the abilities of the *akh*.

mješavina natrijeva karbonata i natrijeva bikarbonata te manje količine kuhinjske soli i natrijevog sulfata. Bijele je boje i ima oblik praha. Smatra se da njegov naziv dolazi od grčkog *nitron* i od egipatskog *netjeri* – “božanski”. Očito se koristio zbog mišljenja da je božanskog podrijetla. Budući da ima karakteristike soli služio je za isušivanje tijela. Tijelo bi se prekrilo hrpom natrona i tako ostavilo nekoliko dana.

Herodot i Diodor spominju uporabu palminog vina za ispiranje utrobe. To vino je zahvaljujući visokom postotku alkohola djelovalo antibakterijski. Koliko je poznato, iako je naziv “mumija” proizašao od bitumena ta se kemikalija relativno rijetko koristila u Egiptu. Palminim vinom prali su se i organi izvađeni iz tijela prije nego što su bili pohranjeni u takozvane kanopske vaze²². Jetra, želudac, crijeva i pluća su nakon pranja palminim vinom bili isušeni tako da su bili prekriveni natronom te umotani u lanene povoje. U jednoj varijanti organi su se odlagali u vaze, a u drugoj su vraćeni natrag u tijelo.

Jedna od najgorih okolnosti pri mumifikaciji tijela koja je trajala danima svakako je bio njegov neugodan miris. Nije teško pretpostaviti da se mrtvo tijelo nakon nekog vremena, unatoč svim tretmanima, počelo rastvarati. Kako bi poboljšali njegov miris, tretirali su ga cimetom i tamjanom. Tamjan je bio sveta tvar koja se uvozila iz zemlje Punt, smještene negdje u Africi. Također, tamjan se prinosisio kao žrtva paljenica u kulturnim hramovima.

Budući da je dehidracija pomoću natrona dovela do rapidnog sušenja kože, a dobro izrađena mumija trebala je zadovoljavati estetske standarde, tijelo bi se naknadno zalijevalo uljima. U tekstovima se govori o cedrovom ulju uvezenom s Krete i iz Biblosa, no neki drže da se učestalije koristilo ulje smreke. Herodot govori o terpentinovom ulju koje se injektiralo u anus. Ova metoda je vjerojatno bila najjeftiniji način čišćenja tijela bez vađenja organa.

²² Ime ovim posudama dali su Grci prema rukavcu Nila, Kanopusu, vjerujući, pogrešno, da se tamo slavi kult Ozirisa u obliku posude.

Chemical substances

The most important substances and chemicals used in the mummification procedure included water, natron, alcohol, bitumen, resin, incense, spices, oils, fats and linen bands. Water was used to wash the body after extracting the organs from the trunk and was generally the main substance of purification in all Egyptian rituals. As far as natron is concerned, it appears in nature as a mixture of sodium carbonate and sodium bicarbonate and a smaller amount of common salt and sodium sulphate. It is a white powder whose name is considered to originate from the Greek *nitron* and the Egyptian *netjeri* – “divine”. It was obviously used due to the belief in its divine origin. Since it has the features of salts it was used to desiccate the body. The body was covered with a pile of natron and was left that way for a couple of days.

Herodotus and Diodorus mentioned the use of palm wine for washing the viscera. Thanks to its high percentage of alcohol, this wine had an antibacterial effect. Although the term “mummy” derives from bitumen, that chemical substance was relatively rarely used in Egypt, at least as far as we know. Before storing them in canopic jars,²² organs were washed with palm wine. Once washed, liver, stomach, intestines and lungs were covered with natron, dried and wrapped in linen bandages. In one type of practice organs were stored in jars, in another, they were put back into the body.

One of the worst circumstances concerning the mummification of the body that lasted for more days was for sure its unpleasant odour. It is not hard to assume that after some time, despite all treatments, the dead body started decomposing. In order to improve its odour, they treated the body with cinnamon and incense. Incense was a sacred substance imported from the land of Punt – located somewhere in Africa – and was used also as a burnt offering in cult temples.

²² Ancient Greeks named canopic jars after the Nile effluent Canopus. They were wrong in their belief that the cult of Osiris in the form of a vessel was worshipped there.

Među bitnim supstancijama koje su bile u uporabi treba još spomenuti mirisnu biljku mirhu i vosak. Pomoću voska na kraju obreda bili su začepljeni tjelesni otvori na glavi (nosnice, uši, usta), a ulje od biljke mirhe koja se u više starih kultura (spominje se i u Starom zavjetu²³) koristila kao miris. Grčki putopisac Herodot je zapisao da je tijelo očišćeno od organa bilo ispunjeno smolom od mirhe i cimetom.

Običaje koje opisuje Herodot može se shvatiti kao elitni, skupi postupak koji se koristio od Novog Kraljevstva nadalje. U njemu se, naime, koriste mirodije i tvari koje su bile preskupe za prosječnog građanina Egipta.

Dakako, svaka izrada mumije završavala je zamatanjem lanenim trakama. Za svako tijelo bilo je potrebno više desetaka, a možda i stotinjak metara lanenih povoja. U skupljoj varijanti između povoja polagani su amuleti od zlata, lapisa ili fajanse, čija uloga je bila da ožive pojedine dijelove tijela kako bi ih duša mogla koristiti na drugom svijetu. Lanene trake finije izrade koristile su se za zamatanje vrata i prstiju koje je bilo delikatno. Kod mumija kraljevskog podrijetla ruke su se zamatale s dlanovima položenim na prsa, dok su kod običnih ljudi bile položene na abdomen ili umotane u spuštenom položaju uz tijelo. Na kraju je čitavo tijelo još jednom omotano većim komadima lana umočenim u smolu koji su ruke priljubili tijelu i spojili noge.

Mumija je mogla biti prekrivena obojenim ukrasnim platnima, ili stavljena u obojenu i ispisanu kartonažu²⁴ ukrašenu bogatom ikonografijom – zaštitničkim božanstvima, svetim simbolima, imenima, žrtvenim formulama. Sjajan primjer takve zaštite mumije je kartonaža kojom je omotana mumija Amonove svećenice Kaipamau iz 22. dinastije. I konačno, tijelo je pohranjeno u drveni ili kameni sarkofag čija je izrada zahtijevala posebnu pozornost i obradu. Umrlo osoba s kojom su obavljani svi ovi obredi i tako bila sahranjena trebala je prema egipatskoj mitologiji uskrsnuti i nastaviti život u nevidljivim dimenzijama astralnog svijeta Duata.

²³ *Pjesma nad pjesmama*. 13.

²⁴ Kartonaža – smjesa slična kartonu koja se izrađivala od platna ili papirusa i blata.

For a well-prepared mummy to meet certain aesthetic standards the body was poured with oils since dehydration with natron led to rapid skin drying. For that purpose, cedar oil is mentioned in the texts that was imported from Crete and Biblos. Still, some authors believe juniper oil was more frequently used. Herodotus spoke about turpentine oil that was injected into the anus. This method was probably the cheapest way of cleaning the body without removing the organs.

Among important substances used, the aromatic plant myrrh must also be mentioned and wax. Wax was used at the end of the ritual to block body cavities on the head (nostrils, ears, mouth), and myrrh oil, which is mentioned in many ancient cultures (also in the Old Testament²³) was used as a perfume. The Greek travel writer Herodotus wrote that the body cleaned of organs was packed with myrrh resin and cinnamon.

The practice described by Herodotus may be understood as an elite, expensive procedure used since the New Kingdom. In fact, the spices and substances used in those customs were too expensive for the average Egyptian citizen.

The final stage in the preparation of mummies was of course to wrap them up in linen strips. More tens or maybe even hundreds of meters of linen were used for wrapping a single body. In more expensive procedures, amulets of gold, lapis or faience were placed between the layers of wrappings and their role was to reanimate single parts of the body so that the soul could use them in the afterlife. Strips of finer linen were used for wrapping the neck and fingers, which was a very delicate task. Mummies of royal descent had their arms wrapped with the palms positioned on the chest, whereas in those of common people the arms were either on the abdomen or wrapped in a stretched position alongside the body. Finally, the whole body was once again wrapped with larger pieces of linen tinged in resin that made the arms adhere to the body and joined the legs.

²³ *Song of Songs* 13.



KARTONAŽA KAIPAMAU
CARTONNAGE KAIPAMAU



Potpuno omotana MUMIJA ŠEPENUN
An entirely wrapped MUMMY OF SHEPENUN



A mummy could have been covered with tinged decorative linen, or placed in a painted cartonnage²⁴ covered in writing and decorated with rich iconography including protection deities, holy symbols, names and sacrificial formulas. A splendid example of such a protection of mummies is the cartonnage used to wrap Amon's priestess Kaipamau from the 22nd dynasty. And, finally, the body was placed into a wooden or stone sarcophagus, whose making required special attention and processing. According to Egyptian mythology, a deceased person who went through all those rituals and was buried in that way was supposed to resuscitate and continue their life in the invisible dimensions of the astral world of the Duat.

²⁴ Cartonnage – a mixture similar to cardboard composed of either linen or papyrus and mud.



KANOPSKE VAZE

Kanopske vaze bile su posebne kultne posude za odlaganje organa izvađenih iz tijela. Bilo da su samo oprani vodom i konzervirani uljem, ili da su, u drugoj varijanti, umotani u lanene po-voje, unutarnji organi su se odlagali u ove četiri vaze. Kanope ili kanopske vaze najčešće su se izrađivale od alabastra. One su uvijek istog oblika – blago se šire prema gore te lagano sužavaju prije samog vrha s otvorom. Poklopci prikazuju glave četiriju duhova-čuvara. To su Imset, Hapi, Duamutef i Kebehsenuf – čovjek, pavijan, čagalj i sokol. Čini se da su organi bili shvaćeni kao prepreka zagrobnom životu. Iz tog razloga trebalo ih je neutralizirati, ali ipak sačuvati u blizini mumije.



CANOPIC JARS

Canopic jars were special cult vessels designed to store the internal organs of the deceased. Regardless of the fact whether they were washed with water alone or preserved with oils, or even, in another process, wrapped in linen strips, internal organs were stored in those four jars. Canopic jars were mostly made of alabaster. They were always the same shape – they were lightly broader upwards but with a narrowing before the very top of the opening. Their covers were shaped in the form of four ghost-guards: Imset, Hapi, Duamutef and Kebehsenuf – a man, a baboon, a jackal and a falcon. Apparently, organs were considered as an obstacle to the afterlife and therefore had to be neutralised but still preserved in the vicinity of the mummy.



Značenje mumifikacije životinja

Dosta je nagađanja o tome kakav je točno bio odnos Egipćana prema životinjama, no ni jedna dosadašnja studija ne daje naslutiti da je taj odnos bio drugačiji od onoga u bilo kojoj drugoj civilizaciji. Dok se jedne životinjske vrste promatraju samo kao hrana i predmet lova, druge se uzgajaju i čuvaju, treće su kućni ljubimci. Neke su životinje bile predmet kulta. Takve poput Apisova bika, ili svetih ibisa i krokodila, mogle su se držati u posebnim uvjetima u hramovima. Život takvih životinja bio je ispunjen ljudskom pažnjom. Moglo bi se zaključiti da je u današnje vrijeme slično sa psima i mačkama koji se uređuju i vode na natjecanja u ljepoti, ili s rasnim, trkaćim konjima. Neki su istraživači pokušali dokazati da Egipćani nisu bili okrutni i ubijali životinje, primjerice svete ibise, samo da bi iz njih napravili mumije koje su se prodavale kao relikvije. Drugi pak tvrde da je ta praksa bila česta. Također, jedan dio životinja tretiran je kao kućni ljubimci. Uglavnom su to bili psi i mačke, a mnogi od vlasnika poželjeli su ponijeti te ljubimce sa sobom na drugi svijet pa su ih mumificirali.

Predmet mumificiranja mogla je biti bilo koja životinja. U Nacionalnom muzeju u Kairu mogu se naći psi, krokodili, grgeči i druge goleme riječne ribe, telad itd. No stotine tisuća životinjskih mumija koje su bile posvećene određenim božanstvima ipak pripadaju nekolicini vrsta. U mjestu Tuna el Gebel otkriveno je gotovo pola milijuna ibisa i pavijana posvećenih bogu Totu – izumitelju pisma i zaštitniku mudrosti i znanja. Sveti bikovi boga Apisa bili su pohranjeni u goleme kamene sarkofage kod Sakare. Tamo je otkriven i velik broj životinjskih mumija u galerijama ispod Đoserove piramide. Mumificirane životinje pronađene su i na mnogim drugim mjestima u Egiptu – od delte Nila do Asuana. Mumifikacija životinja, s druge strane, mogla je imati i neke praktične razloge. Svećenici “kuće ljepote”, *per-nefer*, mogli su na životinjama izučiti umijeće mumificiranja.

The meaning of animal mummification

There has been much guesswork about the exact relationship Egyptians had towards animals. So far no study has given any hints of a relationship that would significantly differ from the one found in any other civilisation. Certain animal species were considered only as a source of food and hunting objects, other species were raised and protected, while others again were perceived as pets. Some animal species were cult objects, like the Apis Bull, the Sacred Ibis and crocodiles that were kept in special conditions in temples. The life of such animals was filled with human attention and we might conclude that the attitude of Egyptians was similar to the attitude we have today towards cats and dogs that are made pretty for participating at beauty contests, or towards thoroughbred race-horses. Some researchers have tried to prove that Egyptians were not cruel and did not kill animals - like for instance the Sacred Ibis – with the only purpose of mummifying and selling them as relics, others however, claim that this was common practice, although certain animals, mainly dogs and cats, were treated as pets and were mummified because their owners wanted them to join them in the afterlife.

Any animal could have been subject to mummification. In fact, in the Cairo National Museum dogs, crocodiles, perches and other huge freshwater fish, calves etc. can be seen. Hundreds of thousands of animal mummies that were dedicated to certain deities belong to few species. In Tuna el Gebel almost half a million ibises and baboons were discovered devoted to the god Thoth – the inventor of writing and protector of wisdom and knowledge. Sacred Apis Bulls were deposited in huge stone sarcophagi close to Saqqara, where a large number of animal mummies were discovered in the galleries beneath Djoser's pyramid. Mummified animals were also discovered in many other places in Egypt, from the delta of the Nile River to Asuan. It is said

Jedino uistinu specifično za njihov odnos prema životinjama je teološko promišljanje. Ono polazi od toga da se božanska moć utjelovljuje u sva bića pa tako i životinje, dok primjerice, Biblija čovjeka postavlja iznad, odnosno kao onoga tko raspolaže životinjama. Fascinacija Egipćana životinjama dovela je do raznih vjerovanja, nazivlja mjesta, simbola gradova, pa i znakova u pismu koji prikazuju životinje. Svaka je životinja pokazivala neke karakteristike, pa je tako nilski konj bio simbol snažne majke zaštitnice, a sokol solarna ptica i gospodar neba, i slično.

U Arheološkom muzeju u Zagrebu čuva se pet mumificiranih cjelina životinjskih ostataka. To su mumija od ostataka mačke, ibisa, jedne manje ptice, i neki skupni neidentificirani životinjski ostaci. Naime, jedan od običaja u faraonskom Egiptu bio je pakiranje nasumično odabranih kostiju u jednu cjelinu koja se nudila na dar bogovima jednako kao što je to bio slučaj s cjelovitim životinjskim mumijama.

Papyrus Zagreb 597-2²⁵ iznimno je rijedak dokument koji opisuje mumificiranje svetog bika posvećenog Apisu. Tekst svjedoči o događaju u vrijeme faraona Nektaneba II. (360.-343. pr. Kr.) za čije vladavine umire jedan od svetih bikova. Naime, Egipćani su tražili životinju koja je morala na sebi imati točno određene šare i znakove kako bi je proglasili svetim Apisovim bikom koji utjelovljuje to božanstvo. Takav bik držao se i čuvao kao sveta životinja i nakon što bi uginuo trebao je biti mumificiran i pokopan u grobnici sa svim počastima. Egipćani su ovaj običaj održavali tisućljećima²⁶ pa je i njihova mržnja prema perzijskim okupatorima bila tim veća što se njihov satrap izrugivao tom običaju. U tekstu svećenik objavljuje faraonu da je Apis uzašao na nebo te počinju pripreme za njegov ukop. Drugi dio teksta sastoji se od uputa kako mumificirati bika nakon što je bio ritualno oplakan.

²⁵ Prijevod prema Pierre Meyrat, *The First Column of the Apis Embalming Ritual : Papyrus Zagreb 597-2*, in Joachim F. Quack (ed.), *Ägyptische Rituale der griechisch-römischen Zeit, Orientalische Religionen in der Antike (ORA)*, u tisku. Inače, ostatak ovog papirusa čuva se u Beču.

²⁶ Po Manetonu (*Aegyptiaca* Fr. 8, 2. prema Sinkelu) kult svetih bikova bio je utemeljen već za 2. dinastije u gradu Memfisu.

that there might have been certain practical reasons behind animal mummification: an animals the priests of the “houses of beauty”, *per-nefer*, were able to improve mummification skills.

The only real peculiarity concerning Egyptians' relationship towards animals was their theological understanding of them. Unlike the Bible that positions men over animals, i.e. like the ones who rule them, Egyptians believed that the divine power was embodied in all beings and thus also in animals. In fact, their fascination with animals led to various beliefs concerning the names of places, symbols of towns and signs in the writing that depict animals, which were each characterised by certain features, for instance, the hippopotamus was the symbol of a strong mother protectress, while the falcon was a solar bird and the ruler of the sky etc.

There are five mummified units of animal remains stored at the Archaeological Museum in Zagreb. These are the mummified remains of a cat, an ibis, a smaller bird and some grouped unidentified animal remains. One of the practices in pharaonic Egypt was to pack together into a whole randomly selected bones and offer them to the gods in the same way as entire animal mummies.

Papyrus Zagreb 597-2²⁵ is an exceptionally rare document that describes the mummification of the sacred bull devoted to Apis. The text bears witness to the event that took place at the time of pharaoh Nektaneb II (360-343 BC) during whose rule one of the sacred bulls perished. In fact, Egyptians sought an animal that had to have precisely defined markings and symbols, in order for it to be proclaimed a Sacred Apis Bull embodying that deity. Such a bull was held and guarded as a sacred animal and after death it had to be mummified and buried in a tomb with all the honours. Egyptians practiced that ritual for millennia²⁶

²⁵ Translation: Pierre Meyrat, *The First Column of the Apis Embalming Ritual : Papyrus Zagreb 597-2*, in Joachim F. Quack (ed.), *Ägyptische Rituale der griechisch-römischen Zeit, Orientalische Religionen in der Antike (ORA)*, in print. The remains of this papyrus are stored in Vienna.

²⁶ According to Manetho (*Aegyptiaca* Fr. 8, 2. According to Sinkel) the cult of the sacred bulls was established already during the 2nd dynasty in the town of Memphis.

17. ... Apisovo mjesto. Radnje koje će biti obavljane za njega u njegovom svetištu. Uab svećenici ovog boga rasprostrijet će (lan) duž čitave kapele.

18. ... čitavo mjesto. Postavit će oni veliki stolak ispod (njegovog) vrata, a mali ispod njegove brade. Oni će

19. ... ili dva svećenika uab, ovog boga koji su uvježbani balzamatori tajnovitog lica. Oni će otvoriti usta boga.

20. ... (on će staviti) svoju ruku na usta boga. On će staviti kuglice voska, mirte, mješavine ulja od pistacija, ili dva čepića od drveta sikomore, u promjeru širine jednog palminog lista, širine triju znakova.

21. ...kad bude ležao na jednoj strani bit će okrenut na drugu. Oni će omotati obje s platnom hebes, na desnoj i lijevoj strani usta boga, između zuba.

22. ... u njegovim ustima. On će sakupiti sve što nađe u ustima ovog boga. On će obrisati sve otvore na njegovoj glavi. On će baciti sve ostatke hebes platna.

23. ... postavite i provjerite. On će obući platnom hebes unutar njegovih usta kako daleko mu doseže ruka. On će započeti balzamiranje očnih kapaka. On će ...

24. On će započeti balzamiranje nosa. On će omotati platnom hebes, on će obući u platno hebes. On će započeti s balzamiranjem rogova i ušiju. On će ...

I tako, malo po malo, čitav bik bio bi obrađen istim tehnikama koje su se primjenjivale na ljudima. Grobnica Apisovih bikova u Sakari jedno je od najimpresivnijih mjesta u Egiptu. U njoj su sačuvani golemi kameni sarkofazi u koje su sveti bikovi bili pohranjeni.

PAPIRUS / POPYRUS Zagreb 597-2 (AMZ)

IBIS I MAČKA (AMZ)

Među svetim životinjama mumificiranim sa svrhom očuvanja božanskih inkarnacija najviše je mačaka posvećeno božici Bastet te ibisa i pavijana bogu Totu.

AN IBIS AND A CAT (AMZ)

Among the sacred animals mummified with the aim of preserving divine incarnations the majority are cats devoted to the goddess Bastet, and ibises and baboons devoted to the god Thoth.

so that their hatred towards the Persians was all the bigger for their satrap mocked that custom. In the text the priest communicates to the pharaoh that the Apis has ascended to the heavens and that the preparations for its burial can begin. The second part of the text consists of instructions on how to mummify a bull after the mourning has been performed in a ritual.

17. ... Apis'es place. The actions that shall be performed for him in his shrine. Uab priests of this god shall spread linen across the entire chapel.

18. ... the entire place. They shall place a large bench below (his) neck, and a small one below his chin. They shall ...

19. ... or two priests uab, of this god who are skilled embalmers with a secret face. They shall open the mouth of the god.

20. ... (he shall put) his hand on the mouth of god. He shall place small balls of wax, myrth, a mix of pistachio nut oil, or two little taps of sycamore tree of the diameter of the broadness of a palm leaf, broad as three signs.

21. ...when lying on one side he shall be turned to the other side. They shall wrap both sides with hebes linen on the left and right side of the mouth of the god, between the teeth.

22. ... in his mouth. He shall gather everything he can find in the mouth of the god. He shall clean all the openings on his head. He shall throw away all the remains of the hebes linen.

23. ... place and check. He shall fill his mouth with hebes linen as far as his hand can reach. He shall start the embalming of the eyes. He shall.

24.He shall start the embalming of the nose. He shall wrap the hebes linen and shall pack with hebes linen. He shall start the embalming of the horns and the ears. He shall ...

And so, bit by bit, the whole bull was treated with the same techniques that were applied to men. The tomb of Apis' Bulls, the Serapeum, in Saqqara is one of the most impressive places in Egypt. In it, stone sarcophagi have been preserved in which the sacred bulls were buried.

Fragment of an ancient Egyptian papyrus scroll with hieroglyphic text. The text is arranged in approximately 25 horizontal lines. The scroll is heavily damaged, with significant portions missing, particularly in the center and bottom. A prominent red ink mark is visible in the lower-middle section of the text.





Moderni svijet i mumije

Mummies and the modern world

Mit o oživljenim mrtvacima, neumrlima, vampirima i sličnim parafenomenima koji je zaživio u zapadnoj kulturi katkad se povezuje i s mumijama. Dok su istraživači u Egiptu krajem 19. i početkom 20. stoljeća nailazili na skrivene podzemne prostorije s mnoštvom mumija, u Europi se još od vremena romantizma razvijala i književnost strave kao zasebna grana tog pokreta. Kako je romantizam težio dalekim i nepoznatim krajevima, Egipat se uklapao u takvu sliku, a mumije su se pokazale odličnom nadogradnjom promišljanja o čudovištima iz mraka ljudske podsvijesti. Ustajanje mrtvih je nešto strano što se protivi razumu. Sigmund Freud²⁷ tvrdio je da u čovjeku izaziva nelagodu, tjeskobu i jezu ono što doživljava kao strano i nepoznato. Mumija koja ustaje iz groba u našoj mašti nije samo oživljeni mrtvac, već izaziva stravu i činjenicom da nas od njezine smrti dijele tisućljeća. Zato u hororima mumije oživljavaju i napadaju ljude ili se putem magije koriste njihovom energijom kako bi se ponovno pretvorile u ljude. Ove ideje su dio naslijeđa naše kulture i njezinog nesvjesnog koje se ne može ignorirati.

Filmski klasik "Mumija" Karla Freundta iz 1932. godine jedan je od najstarijih filmova u kojima se publika straši mumijom koja ustaje iz groba i napada ljude. Imhotep, znalac koji

The myth of the revived dead, the undead, of vampires and similar para-phenomena that took hold in western culture is sometimes associated with mummies. In the 19th and 20th centuries researchers in Egypt discovered underground premises with a multitude of mummies, while horror fiction was developing in Europe during the romantic period as a separate section of that movement. Since Romanticism streamed towards far and unknown landscapes, Egypt fit quite well into that picture, and mummies proved to be an excellent expansion of the considerations about monsters inhabiting the dark human subconscious. The rising of the dead is something extraneous, contrary to common sense. Sigmund Freud²⁷ claimed that everything that is perceived as extraneous and unknown causes feelings of discomfort, anxiety and thrill. A mummy rising from the grave does not represent in our imagination only a revived dead, but also causes horror since it is millennia that separates us from its death. Therefore, in horror films mummies become alive and attack people or use their energy through magic only to be transformed again in humans. These ideas are part of the heritage of our culture and its unconscious that cannot be neglected.

²⁷ S. Freud: *Pojam jeze u književnosti i psihologiji*. Zagreb 2010.

²⁷ See: S. Freud, *Das Unheimliche*, in *Freud-Studienausgabe, Bd. IV., Psychologische Schriften*, Frankfurt a. M.: S. Fischer, 1970

je živio u starom Egiptu, posegnuo je za zabranjenim znanjem ukravši sveti papirus s moćnim magijskim izričajima, te biva osuđen na smrt, i to tako da bude živ mumificiran. No njegovo znanje i tijelo koje su pronašli britanski arheolozi vraćaju ga u život, i on počinje tražiti svoju ljubav Ankhesenamun koja se u međuvremenu ponovno utjelovila u lijepoj Helen Grosvenor. Na vrhuncu zapleta Imhotep održava ritual kojim će Helen spojiti s njezinom dušom. No kako bi to postigao mora je prvo ubiti. Helen dvoji. Razapeta je između svog drevnog i modernog identiteta te poziva u pomoć Izidu. Božica intervenira u posljednjem trenutku i pretvara Imhotepa ponovno u mumiju.

U zadnjih desetak godina nastala su tri nastavka najnovije verzije iste priče ojačane modernom tehnologijom vizualnih efekata. Ipak, stari film u kojem Imhotepa igra Amerikanac Boris Karloff ostat će upamćen kao originalna verzija priče.

Ideja s probuđenom mumijom blisko je povezana i s motivom slavnog romana "Frankenstein" Engleskinje Mery Shelly koji je također ekraniziran 1910. godine. Oživljeni monstrum kojeg autorica zamišlja kao čovjeka sastavljenog od dijelova više mrtvih ljudi animiran je pomoću visokog napona, no njegova istinska ljudskost do kraja ostaje problematična. Čudovište doktora Frankensteina kao i mumije u većini filmova završava tragično. *Horror* tematika o mumijama i drugim ponovno oživljenim bićima je neka vrst mitologije neprirodnoga i jezivog, ali i onoga što ne može dugo potrajati. Njegova poruka je da bi neumrlost ili povratak iz smrti bio užasna pogreška protiv prirode. U istu kategoriju spadaju i vampiri, s tom razlikom da su oni magična bića koja raspoložu paranormalnim sposobnostima. Kombinacija jednog i drugoga iskoristila se u modernoj sagi o Imhotepu autora Stevena Somersa čiji se prvi nastavak pojavio 1999. godine. Zli čarobnjak koji se konzumacijom energije od živih ljudi ponovno pretvorio u čovjeka, nazvan je također po Imhotepu - graditelju Đoserove piramide u Sakari, što, barem u očima egiptologa, ostavlja dojam bizarnosti.

The 1932 film classic "The Mummy" directed by Karl Freund is one of the oldest films in which the public was scared by a mummy that rose from the tomb and attacked people. Imhotep, an sage who lived in Ancient Egypt, seized for prohibited knowledge by stealing a holy papyrus with powerful magical spells and was therefore mummified alive. His knowledge and the fact that he was found by some British archaeologists, brought him back to life. Imhotep started seeking his lover Ankhesenamun, who was reincarnated in the meantime in the beautiful Helen Grosvenor. At the peak of the plot Imhotep carries out a ritual that would make Helen join her soul, but, in order to achieve that, he has to kill her first. Helen has doubts, she is stretched between her ancient and modern identities and invokes Isis to help her. The goddess intervenes in the last minute and turns Imhotep into a mummy again.

In the last decades three sequels of the newest version of the same story followed strengthened by modern technology visual effects, although, the old film featuring the American Boris Karloff will be remembered as the original version of the story.

The idea of the awoken mummy is closely connected with the motive of the famous novel "Frankenstein" by the English novelist Mery Shelly which was also filmed in 1910. The author imagined a revived monster to be made up of pieces of more dead people and animated by high voltage, but its true humanness remains problematic until the end. Doctor Frankenstein's monster as well as mummies have a tragic end in most films. The topic of horror concerning mummies and other revived creatures is a type of mythology of the unnatural and of thrill, but also of something that cannot last for long. Its message is that undeadness, or a return from death, would be a horrid mistake against nature. Vampires belong to the same category with a difference that they are magical creatures that avail of paranormal abilities. A combination of both is employed in the modern saga of Imhotep directed by Stephen Somers whose first sequel appeared in 1999. By using the energy of living people, the evil magician is transformed

Ipak, sama zamisao o protuprirodnoj obnovi života nakon smrti uistinu jest nastala u faraonskom Egiptu. Potvrđuju to i *Tekstovi piramida* i *Knjige mrtvih*. Čak i sam običaj žrtvovanja hrane i pića nečijem *ka* može se shvatiti kao misao koja vodi prema ideji vampirizma, ili barem u određenoj mjeri podsjeća na nju. No mitologija zagrobnog života u Egiptu je ipak shvaćena sasvim metafizički. Nitko, naime, nije pomišljao da mrtvo balzamirano tijelo ustane i započne novi život.

Misao o ustajanju mumija dosta govori o infantilnosti naše civilizacije u njezinom odnosu sa smrću. U modernom urbanom društvu ima manje kontakta s mrtvima nego što je to bio slučaj ranije. Umrli se sakrivaju u zatvorenim prostorima bolnica i pogrebnih društava kao da nam ne žele pokazati kako smrt uistinu izgleda.

again into a man, called also Imhotep – after the builder of Djoser's pyramid in Saqqara -, which, at least in the eyes of Egyptologists, leaves the impression of bizarreness.

Still, the idea of the unnatural renewal of life after death was originated in pharaonic Egypt. This is confirmed in the *Pyramid Texts* and the *Books of the Dead*. Even the custom itself of offering food and drinks to someone's *ka* may be understood as a thought leading to the idea of vampires or at least recalls it to a certain extent. However, in Egypt the mythology of the afterlife was conceived entirely metaphysically. No one believed that the embalmed dead body would rise and start a new life.

The idea of the rise of mummies tells a lot about the infantilism of our civilisation in its relation to death. In our modern urban society there are much less contacts with the dead than there was in the ancient times. Nowadays the dead are hidden in closed areas of hospitals and undertakings, as if they did not want us to see what death really looks like.





Literatura Bibliography

- Campbell, J., *Oriental Mythology*. New York 1991.
- Dunand, F. – Lichtenberg, R., *Mummies – A Journey Through Eternity*. London 1994.
- Eliade, M., *Histoire des croyances et des idées religieuses*. Pariz 1989.
- El Mahdy, Ch., *Mummies - Myth and Magic*. London 1989.
- Faulkner, R. O. *The Ancient Egyptian Pyramid Texts*. Oxford 1969.
- The Ancient Egyptian Book of the Dead*. London 1985.
- The Ancient Egyptian Coffin Texts*. 1973.
- Herodot, *Historie* (prijevod Aubrey de Sélincourt) London 1972.
- Hobson, Chr., *Exploring the World of the Pharaohs*. London 1987.
- Hoffman, M. A., *Egypt before the Pharaohs*. London 1980.
- Morenz, S., *Ägyptische Religion*. Stuttgart 1960.
- Munro, I., *Spruchvorkommen auf Totenbuch-Textzeugen der Dritten Zwischenzeit*. Studien zum Altagyptischen Totenbuch 5. Wiesbaden 2003.
- Spencer, A. J., *Death in Ancient Egypt*. Harmondsworth 1982.
- Uranić, I. *Stari Egipat*. Zagreb 2001.
- Prilozi o skarabjima srca u Arheološkom muzeju u Zagrebu. *Vjesnik Arheološkog muzeja u Zagrebu*, 3. s, XXIV-XXV. 1997
- Book of the Dead Papyrus Zagreb 601*. Studien der Altägyptischen Kultur 33, Hamburg 2005.



Mumije i znanost *Mummies and Science*

Mislav Čavka

Anja Petaros

Mumije i radiologija

Mummies and Radiology

Interes za znanstvena istraživanja mumija pojavio se nakon što su otkrivena velika podzemna skloništa kraljevskih mumija u blizini Luksora. Te su faraonske mumije privukle veliku pozornost javnosti. Pružila se prilika da znanost istraži tijela slavnih vladara i sazna kakve su građe bili, od kojih su bolesti patili i od čega umrli veliki kraljevi poput Ramzesa II.

Interes medicine za mumije javlja se vrlo rano, već u prvom stoljeću grčko-rimski liječnici preporučuju prah mumije kao lijekovit. S tom praksom nastavlja i Avicena, najpoznatiji liječnik iz arapskog svijeta (iako Perzijanac) te kasniji arapski liječnici od kojih se ta praksa širi zapadnom Europom i kasnije svijetom. Već se u 16. stoljeću, otac kirurgije Ambroise Paré usprotivio tom običaju tvrdeći da se stari Egipćani nisu mumificirali da bi ih nakon nekoliko stoljeća jeli Europljani. Unatoč tome u pojedinim se ljekarnama prah mumije kao lijekovito sredstvo moglo naći sve do 20. stoljeća. Tek u 19. stoljeću one prestaju biti lijek i postaju predmet znanstvenog interesa jer se

Interest in the scientific research of mummies arose after the discovery of large underground shelters of royal mummies close to Luxor. The public devoted much attention to those pharaonic mummies: science was given the possibility to examine the bodies of famous Egyptian kings like Ramses II and find out what their constitution was, from what illnesses they suffered and of what they died.

Medicine's interest in mummies arose very early: already in the first century Greco-Roman physicians recommended mummies' powder for its curative properties. This practice was carried on by Avicena, the most famous physician of the Arabic world (although a Persian) as well as by later Arabic physicians who spread that practice across Western Europe and the rest of the world. Already in the 16th century, Ambroise Paré, the father of surgery, opposed that practice claiming that Ancient Egyptians were not mummified so that Europeans could eat them a couple of centuries later. In spite

počinje shvaćati da oni predstavljaju neotvoreni prozor u povijest medicine i kasnije antropologiju. Jedini je način proučavanja bila patološka sekcija što je neizbježno dovelo do uništenja uzoraka. Tek otkrićem roentgen-skih (RTG) zraka 1895. postaje moguće neinvazivno proučavanje. Tim se otkrićem rađa radiologija, a samo nekoliko mjeseci kasnije u Frankfurtu se snimaju prve ljudske i mačje mumije na roentgenu, što se smatra početkom paleoradiologije. Paleoradiologija je znanost koja se bavi proučavanjem arheološkog materijala «imaging» (slikovnim) metodama. U Hrvatskoj je ova znanost razvijana od samih početaka svjetske paleoradiologije; početkom prošlog stoljeća Dragutin Gorjanović Kramberger snima fosilne ostatke hominida iz Krapine na aparatu u bolnici Sestara milosrdnica u Vinogradskoj ulici. Više od 70 godina RTG je bio jedina metoda na raspolaganju, što je poprilično ograničavalo znanstvenu spoznaju jer RTG superponira sve snimljene slojeve, a osim toga i nema veliku razlučivost mekih tkiva te su samo kosti mogle biti adekvatno analizirane. 70-ih se godina prošlog stoljeća razvija tehnologija kompjutorizirane tomografije (CT) te se vrlo brzo i ona primjenjuje na mumijama. Radi se o slojevnoj tehnici, dobijenih također s RTG cijevi, no koja rotira oko objekta snimanja. To omogućava dobivanje slojeva debljine nekoliko centimetara bez superpozicije, a kasnije razvijanjem softwera i novih generacija CT aparata sve tanje slojeve (danas debljine do 0,5 mm), koji se kasnije mogu kompjutorski obraditi i dobiti trodimenzionalne rekonstrukcije koje omogućavaju, na primjer, virtualno odmatanje zavoja ili uklanjanje mekog tkiva. Unatoč visokoj prostornoj rezoluciji, CT ima manju kontrastnu rezoluciju od magnetske rezonancije (MR). Magnetska rezonancija koristi vrlo jako magnetsko polje (30.000 puta jače od magnetskog polja zemlje) u kombinaciji s radiofrekventnim pulsevima da bi dobila signal iz nevezanih protona vodika kojih ima znatna količina u vodi u tijelu. S obzirom na to da ljudsko tijelo sadrži veliku količinu vode u svim tkivima, signal je vrlo jak. Problem se javlja kod mumija, jer one procesom mumifikacije dehidriraju te je vrlo teško do-

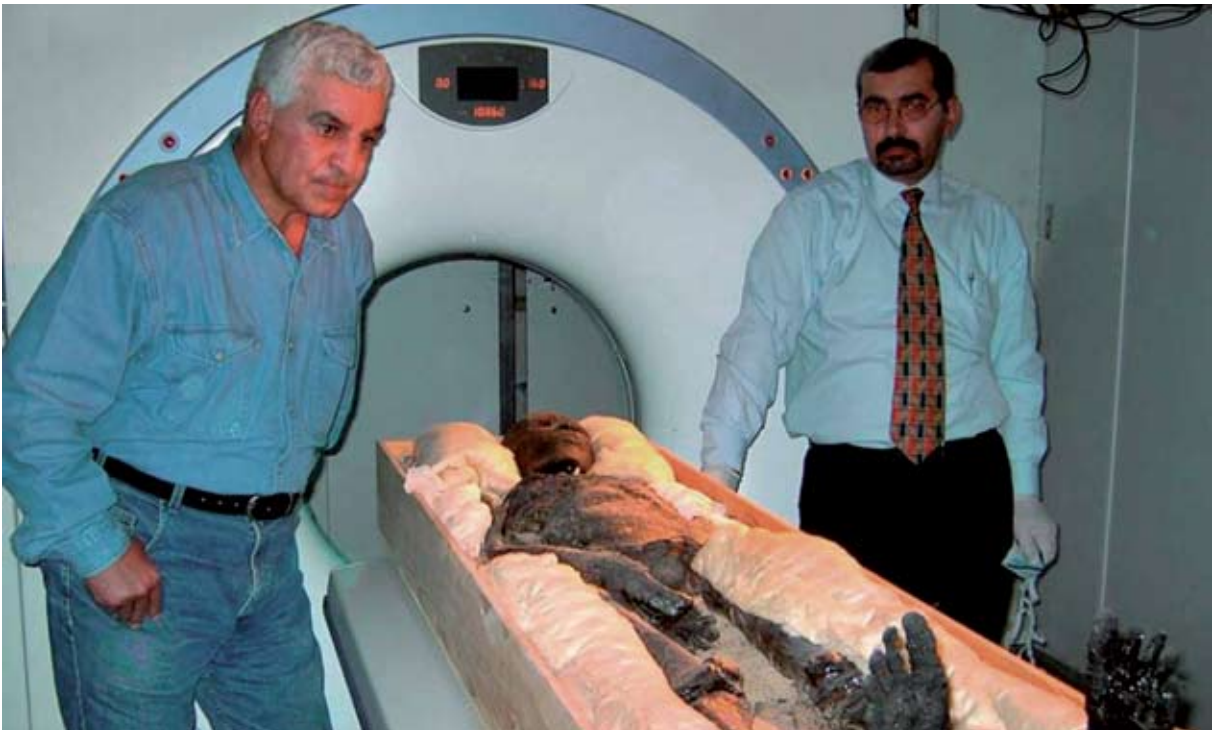of that, mummies' dust could be bought as a medicament in single drugstores until the 20th century. The perception of mummies as a still unopened window to the history of medicine and anthropology developed only in the 19th century, when they finally stopped being considered as a medicament but were rather viewed as objects of scientific interest. The only way of examining them was by means of pathologic section, which unavoidably led to destroying the samples. It was only with the discovery of X-rays (or Roentgen's rays - RTG) in 1895 that a non-invasive examination method became possible. That discovery marked the birth of radiology, and only a few months later in Frankfurt the first human and cat mummies were x rayed, an event marking the beginning of paleoradiology - a science that examines archaeological material by means of «imaging» methods. In Croatia the development of that science has kept the pace with the world paleoradiology since its very beginnings. At the beginning of the last century Dragutin Gorjanović Kramberger screened fossil remains of Krapina hominids at the Sisters of Mercy Hospital in Vinogradska Street. X-rays were the only method available for over 70 years, which significantly limited scientific cognition because superposes all screened slices failing to provide a high resolution of soft tissues, so that only bones could be properly analysed. In the 1970s the technology of computed tomography (CT) developed that was soon applied to mummies. This is a technique that allows different slices to be obtained also by an X-rays tube that is spun around the object to be scanned. This technology allowed slices of few centimetres to be obtained without superposition, and later, with the development of software and new generations of CT devices, it became possible to obtain even thinner layers (reaching 0,5 mm today) that were then computer-processed in order to get three-dimensional reconstructions allowing for example the virtual unwrapping of bandages or the removal of soft tissue. Despite its high spatial resolution, CT has a smaller contrast resolution than magnetic resonance (MR). MR uses a very strong mag-

biti signal. To je postalo moguće kad je docent Ruehli sa suradnicima u Zuerichu uspio dobiti signal novodizajniranom sekvencijom (kombinacija radiofrekventnih pulseva), nazvanom *Ultra short echo time* (UTE). Mi smo u Zagrebu drugi na svijetu upotrijebili ovu sekvenciju na mumijama i prvi put je uspješno primijenili u diferencijalnoj dijagnozi.

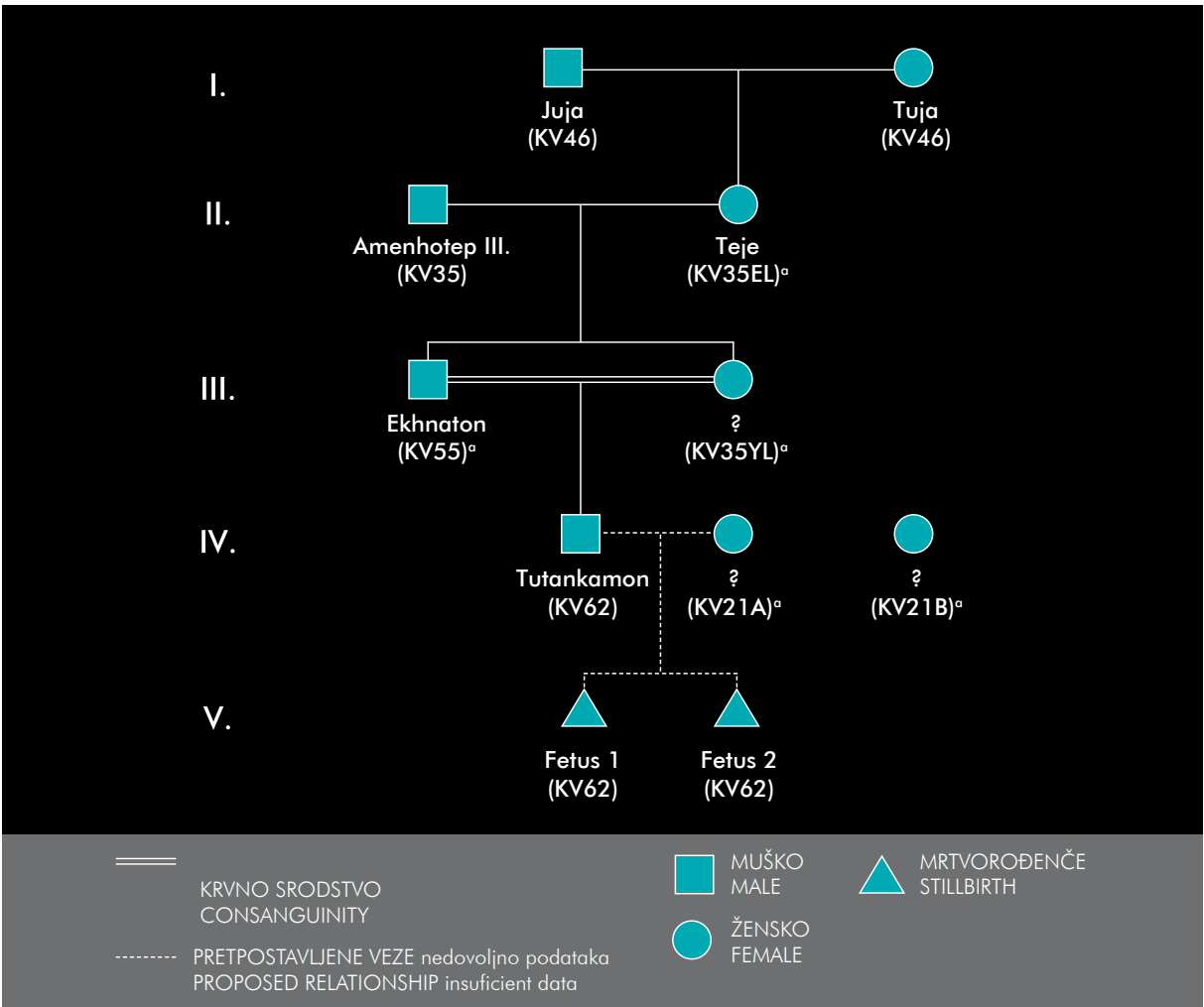
Već 1903. egipatski radiolog dr. Khayat snima mumiju Tutmozisa IV. faraona 18. dinastije. Snimku analizira i Elliot Smith te zaključuju kako faraon nije mogao imati više od 28 godina. Trideset godina kasnije snima se mumija Amenofisa I. (Amenhotepa), drugog vladara 18. dinastije. Zaključeno je da ima od 40 do 50 godina te da se u glavi nalazi gusta masa što se isto vidi u abdomenu, no zbog ograničenja RTG-a nije se moglo detaljnije analizirati. Krajem 60-ih godina prošlog stoljeća prvi put je snimljena mumija Tutankamona, također faraona 18. dinastije, iako tada nevažnog a danas svakako najpoznatijeg egipatskog faraona. Na temelju profilne snimke lubanje zaključeno je da je imao frakturu lubanje i da je najvjerojatnije umro od krvarenja u mozak, što je potaklo publikaciju velikog broja knjiga na temu faraonovog "ubojstva". Tu je došlo do izražaja ograničenje RTG tehnike upravo zbog superpozicije raznih slojeva koji mogu "igrom sjena" ukazivati na nešto što ne postoji. Drugi važni element je svakako da snimke gledaju subspecijalizirani stručnjaci što se 2003. i dogodilo kad je Bower, pedijatrijski radiolog, sa suradnicima pregledao originalne snimke i zaključio da nema dovoljno dokaza o nasilnoj smrti, što je kasnije i potvrđeno CT-om, u sklopu velikog projekta utvrđivanja krvnog srodstva među dostupnim mumijama 18. dinastije riješena je još jedna enigma. U grobnici je nađeno preko 100 štapova za hodanje, čija je namjena razno tumačena, no novim CT-om je nedvojbeno utvrđena Freibergova infrakcija (Köhler II), što odgovara osteonekrozi glave druge metatarzalne kosti te faraon vjerojatno nije mogao hodati bez potpornja. Genetičkim testiranjem utvrđeno

netic field (which is 30.000 times stronger than the magnetic field of the Earth) and radio frequent pulses in order to obtain signals from free hydrogen protons that are largely contained in the water of the body. Since all human tissues largely consist of water, the signal provided is very strong. Problems arose with mummies, since they dehydrated due to mummification, and signals were thus very difficult to obtain. This became possible when Zurich assistant professor Ruehli and associates managed to obtain a signal with a newly designed sequence (combination of radio frequent pulses) called Ultrashort Echo Time (UTE). We in Zagreb were the second in the world to use this sequence on mummies and we successfully implemented it in differential diagnosis for the first time.

As early as 1903 the Egyptian radiologist Khayat scanned the mummy of Tutmoses IV, a pharaoh of the 18th dynasty. Khayat analysed the image together with Elliot Smith and they concluded that the pharaoh could not have been older than 28. Thirty years later the mummy of Amenofis I (Amenhotep), another ruler of the 18th dynasty, was subject to X-rays that showed he was between his 40s and 50s and had a thick compound both in the head and in the abdomen, which could not be analysed into more detail because of the limits imposed by RTG. At the end of the 1960s Tutankhamon's mummy was scanned for the first time. He was also a pharaoh of the 18th dynasty. Although he was not important at that time, nowadays he is the most famous of all Egyptian pharaohs. On the basis of a profile radiogram of the skull, it was possible to conclude that he had a skull fracture and that he most probably died of brain haemorrhage. This discovery triggered the publication of a large number of books on the "murder" of the pharaoh. The limits of the RTG technique became obvious in his case and this as a consequence of superposing various layers that can display in a "play of shadows" something that does not really ex-



Skeniranje Tutankhamonove mumije / Scanning of the Thutankhamun's mummy



je da je mladi faraon bolovao od malarije, a DNA analizom predložena je nova genealogija 18. dinastije koja bi, ukoliko su genetička testiranja točna, trebala biti i konačna. No postoje i ozbiljne kritike izolacije tako stare DNA, jer je prevelika mogućnost kontaminacije s DNA materijalom istraživača.

Godine 1976. Ramzes II. je prebačen u Pariz gdje je snimljen RTG-om, (tada još zlatnim standardom, iako je samo dan kasnije u Torontu prvi put u svijetu iskorišten i CT u paleoradiološke svrhe). Učinjena je i kserografija, neko vrijeme popularna radiološka metoda te je predložena dijagnoza ankilozantnog spondilitisa koja je 2004. dovedena u pitanje te je predložena difuzna idiopatska skeletalna hiperostoza (DISH). Potvrđena je i ateroskleroza u unutarnjoj karotidnoj arteriji, periodontalni apsces i tendinopatije rotatorne manšete.

Godine 1980. objavljen je Atlas kraljevskih mumija u kojem su objavljene snimke kraljevskih mumija iz Arheološkog muzeja u Kairu, no s obzirom na to da su glavni istraživači bili oralni kirurzi naglasak je bio na dentalnoj patologiji.

ist. Another major factor was for sure the fact that images were analysed by subspecialised experts, which was indeed the case in 2003 when Bower, paediatric radiologist and associates, checked the original images and concluded that there was not enough evidence of a violent death. This was later confirmed by a CT performed within the framework of a major project concerning the identification of consanguinity among 18th dynasty mummies, solving thereby yet another enigma. In the tomb, over 100 walking sticks were found, whose purpose has been explained in different ways. However, it was by means of another CT that Freiberg's infraction (Köhler II) was undoubtedly identified, which corresponds to the osteonecrosis of the head of the second metatarsal bone, proving that the pharaoh could not have walked without the support of a walking stick. With generic testing it was established that the young pharaoh suffered from malaria, and with a DNA analysis a new genealogy of the 18th dynasty was suggested, which should be final, providing that generic testings were correct. However, there has been serious criticism concerning the issue of ancient DNA isolation, because of the great likelihood of contaminating that DNA with the researchers' material.

In 1976 Ramses II was transported to Paris where he was exposed to X-rays (still a golden standard at that time, although the very next day in Toronto a CT was used for the first time in the world for paleoradiologic purposes). Also a xerography (a radiologic method that was popular for some time) was performed and ankylosing spondylitis was suggested as his diagnosis. The latter was then questioned in 2004 and diffuse idiopathic skeletal hyperostosis (DISH) was suggested. Finally, atherosclerosis of the internal carotid artery was confirmed, periodontal abscess and rotator cuff tendinopathies.

In 1980 an Atlas of Royal Mummies was published featuring images of royal mummies from the Cairo Archaeological Museum. However, the focus of that atlas was on dental pathology since its main researchers were oral surgeons.

Ljudske mumije iz Arheološkog muzeja u Zagrebu

Human Mummies from the Archaeological Museum in Zagreb

Zagrebačka mumija

Zagrebačka mumija i Zagrebačka lanena knjiga uz Vučedolsku golubicu, portret carice Plautile i još nekolicina spomenika svakako su najpoznatiji i najatraktivniji spomenici današnjeg Arheološkog muzeja u Zagrebu. Oni su izloženi u zasebnoj dvorani uz postav Egipatske zbirke. Na mumiji su obavljena različita znanstvena istraživanja RTG, CT i MR, kao i testiranje starosti, odnosno datiranje, pomoću testa s raspadom ugljika C14. Pokazalo se da je riječ o mumiji žene visoke 164 cm, koja je umrla u starosti od oko 40 godina. Mumija je datirana na 390. godinu prije Krista (s pogreškom od +- 45 godina koja se javlja na toj vremenskoj udaljenosti). Iste su vrijednosti pokazali i povoji.

Krajem 90-ih godina prošlog stoljeća mumija je bila ozbiljno ugrožena procesima raspadanja i gotovo pretvaranja u prah. Na sreću uspjelo se angažirati jednog od najboljih stručnjaka za mumije dr. Nazzena Gabriella iz Vatikanskih muzeja. Gabrielli je analizirao stanje mumije te koristeći se izvornim prirodnim kemikalijama obnovio balzimiranje tijela. Zahvaljujući tom zahvatu 1997. mumija je uspješno konzervirana i spašena od daljnjih procesa raspadanja.

The Zagreb Mummy

Alongside the Vučedol Dove, the portrait of empress Plautila and a few more monuments, the *Zagreb Mummy* and the *Zagreb Linen Book* are certainly the most famous and most attractive exhibits of the Archaeological Museum in Zagreb. They are exhibited in a separate room within the Egyptian collection. The mummy underwent various scientific research: X-rays were taken of it, CT and MR as well as age testing, i.e. dating, by using carbon dating techniques C 14. Testings showed this was the mummy of a woman who was 164 cm tall and who died at the age of about 40. The mummy's age has been dated back to 390 BC (with the possibility of mistake of +- 45 years that can occur for such time distances). The same values were obtained by analysing the bandages.

At the end of the 1990s the mummy was seriously jeopardized by decay processes and was almost turned into dust. Fortunately, one of the best experts for mummies dr. Nazzeno Gabrielli from the Vatican Museums was then employed. Gabrielli analysed the mummy and using authentic natural chemical substances renewed the embalming of the body. Thanks to that intervention in 1997, the mummy was successfully preserved and saved from further decay processes.

Tijelo je mumificirano metodom uobičajenom za stare Egipćane, pa nema dvojbe da se radi o egipatskoj mumiji. To je potvrdio i Gabrielli koji je ispitao sastav preparata koji su se koristili. Mozak je izvađen transnazalno te se u stražnjoj lubanjskoj jami vide ostatci stvrdnute smole. Zagrebačka mumija ima položene ruke uz tijelo te glavu nagnutu prema naprijed što stavlja vratni dio kralježnice u položaj hiperfleksije i neobičnog izgleda na radiološkim snimkama s posljedičnom manjom dislokacijom sedmog vratnog kralješka u odnosu na prvi grudni kralježak, bez sumnje uzrokovano rukovanjem tijela poslije smrti. Grudni je koš jako deformiran, prsna kost je pomaknuta u desnu stranu te je u potpunosti promijenjen njen odnos s rebrima kao i doticaj rebara s kralježnicom. Toraks je evisceriran, no nije popunjen ničim, a prisutno je i nešto ostataka smole. U gornjem abdomenu je identična situacija kao i u toraksu. Tek u zdjelici jasno vidimo rez na lijevoj strani kroz koji su se izvadili organi i nešto stranog materijala kojim se ispunila samo zdjelica. Odnos zdjelčnih kostiju je također promijenjen te su one jedva u kontaktu. No, dakako, mumija i njezini povoji kriju tajnu koja možda nikad neće biti odgonetnuta: Što etruščanski tekst radi na egipatskoj mumiji? Pitanja bez odgovora se samo nižu: Je li možda riječ o Etruščanki koja je živjela u Egiptu? Je li onaj tko je omotao mumiju etruščanskim tekstom učinio to zbog rukopisa ili samo da bi iskoristio lanene trake? Je li možda taj dio povoja bio naknadno dodan? Možda bi sam sadržaj teksta otkrio ponešto, ali taj je jezik znanosti još uvijek uglavnom nepoznat. Civilizacija Etruščana razvijala se i postojala između 9. i 1. stoljeća prije nove ere na području pokrajina sjeverne Italije: Toskane, Umbrije i sjevernog Latiuma, ostavljajući nam brojna umjetnička djela, grobnice, reljefe, brončane i kamene kipove, sarkofage, nakit i mnoge druge predmete. Taj opus danas je arheološko blago starije više od 2000 godina. Ovaj narod naseljavao je, dakle, teritorij trokutastog oblika između Sredozemnog mora, i dviju rijeka: Arna i Tibera. Kako su, međutim, Etruščani bili asimilirani u Rimsko Carstvo njihov je jezik pao u zaborav. Slično je bilo

The body was mummified following the practice that was common to ancient Egyptians, so there is no doubt about that being an Egyptian mummy. This fact was also confirmed by Gabrielli, who examined the composition of the substances used. The brain was extracted trans-nasally, so that the remains of hardened resin could be seen in the posterior cranial fossa. The arms of the Zagreb Mummy are laid down along the body with the head leaning forwards causing thereby the cervical part of the spine to be in a position of hyperflexion and of an unnatural appearance in radiologic images with the consequence of a minor dislocation of the seventh cervical vertebra in relation to the first thoracic vertebra, undoubtedly caused by the posthumous handling of the body. Major deformities appear in the thorax: the sternum is moved to the right-hand side so that its relation to the ribs is entirely changed, as is the relation of the ribs to the spine. The thorax is eviscerated, but it is not packed with anything, and there are some remains of resin. In the upper abdomen the situation is the same as in the thorax. The cut on the left side from where the organs were extracted can be seen only on the pelvis, as well as the remains of some material used to stuff the pelvis. The relations of pelvic bones are also changed so that they are hardly in contact. Still, the mummy and its wrappings conceal a secret that might never be revealed: what is the link between the Etruscan text and the Egyptian mummy? Questions without answers are only lined up in a row: was this an Etruscan woman living in Egypt? Did the person who wrapped the mummy into the Etruscan text do so because of the writing or did they do so only to utilise linen strips? Were those strips maybe added subsequently? Maybe the content of the text would answer to some of those questions, but science still has not been able to decipher that language. The Etruscan civilisation developed between the 9th and 1st centuries BC on the territory of the Italian regions of Tuscany, Umbria and northern Latium, leaving numerous artefacts, tombs, plastics, bronze and stone statues, sarcophagi, jewellery and many other items making up an archaeologi-

i sa starim egipatskim jezikom nakon pada te civilizacije. No za razliku od etruščanskog egipatski jezik sačuvan je u golemom opusu tekstova na hijeroglifima, hijeratici i demotskom pismu, te postoje paralelni tekstovi na egipatskom i grčkom, što je olakšalo njegovo dešifriranje. Kad je riječ o etruščanskom, nije se ni radilo o pravom “dešifriranju”, jer je to pismo neka vrsta abecede koja nije komplicirana za čitanje. Nemoguće je, međutim, s tako malo poznatih tekstova prodrijeti u gramatiku i vokabular etruščanskog jezika. Štoviše, iako iz grobnih prikaza znamo za polaganje nekih vrsta obrednika u grobnice Etruščana, *Liber linteus zagradiensis* je jedni sačuvani etruščanski rukopis na platnu.

ZAGREBAČKA LANENA KNJIGA

na povojima s egipatske mumije, detalj

THE ZAGREB LINEN BOOK

on the wrappings of an Egyptian mummy, a detail

cal treasure that is more than 2000 years old. This people settled the territory of a triangular shape between the Mediterranean Sea and two rivers: the Arno and the Tiber. Since the Etruscans were assimilated into the Roman Empire, their language fell into oblivion. A similar scenario unfolded with ancient Egyptian after the fall of that civilisation. However, unlike the Etruscan language, the Egyptian one was preserved in the huge opus of texts containing hieroglyphics, hieratic and demotic signs. What made its deciphering much easier was the existence of parallel texts in Egyptian and Greek. As far as Etruscan is concerned, there was no real “deciphering”, since that writing is a type of alphabet that is not complicated to read. What is impossible, however, is penetrating into its grammar and vocabulary based on such a small corpus of known texts. Moreover, although we know of the practice of depositing certain books of rites into Etruscan tombs, the *Liber linteus zagradiensis* is the only preserved Etruscan manuscript on linen.



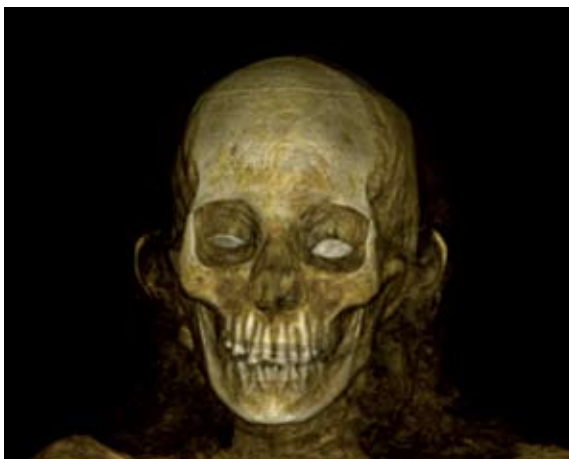Mumija Šepenun

Mumija žene koja se nalazila u trostrukom antropomorfnom sarkofagu koji se sastoji od tri poklopca i dva dna. Svi dijelovi su mu oslikani uobičajenom ikonografijom u bijeložutom tonu. Mumija žene “gospodarice kuće” Šepenun iz ptolemejskog razdoblja (332. – 30. pr. Kr.) umotana je u povoje i prethodno zalivena i pojačana nekom smjesom. Na prednjem dijelu mumije preostali su dijelovi pozlaćene kartonaže (maska) i nakit. Na mumiji je rekonstruiran dio mreže načinjene od staklenih valjčića plave boje, koja je prekrivala cijelo tijelo pokojnice. Radiološki je potvrđeno da se radi o ženskoj osobi. Mozak je izvađen transnazalno, a u lubanji se jasno vide ostatci moždanih ovojnica, no ne i smola u stražnjoj lubanjskoj jami. Očne duplje su ispunjene umjetnim materijalom, a oči su zamijenjene umjetnim očima, vjerojatno staklenim. Vrat je obilno ispunjen lanenim materijalom kako bi se što više ispunio i sličio vratu žive osobe. U toraksu i abdomenu vidimo da se radi o načinu mumifikacije koji je Herodot opisao za najsiromašnije; ispiranje crijeva i držanje tijela u natronu oko 70 dana. Ostatci organa se dobro vide, kao i ostatci smole koja je služila za ispiranje.

70

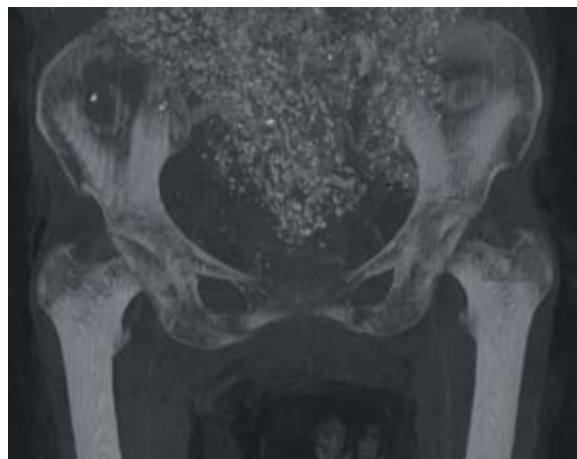CT 3D volume rendering technique (VRT) rekonstrukcija lubanje / skull reconstruction

CT maximum intensity projection (MIP) rekonstrukcija zdjelice / pelvis reconstruction



The Shepenun Mummy

The mummy of a woman found in a three-partite anthropomorphic sarcophagus consisting of three covers and two bottoms. All parts are painted with the common iconography in white-yellow nuances. The mummy of the woman “the mistress of the house” Shepenun of the Ptolemaic Period (332 – 30 BC) is wrapped in strips, previously splashed and reinforced with a certain mixture. On the front side of the mummy pieces of gilded cartonnage (mask) and jewellery have remained. Part of the net of glass blue rolls has been reconstructed on the mummy, which entirely covered the body of the deceased woman. Radiologic scan was used to confirm that it was a female person. The brain was extracted trans-nasally and in the skull the remains of meninges were found but no resin on the posterior cranial fossa. Orbital cavities were packed with some artificial material, and artificial eyes probably made of glass replaced real ones. The neck was generously packed with linen in order to make the mummy look as similar as possible to a living person. The analysis of the thorax and the abdomen revealed the type of mummification procedure used in her case that corresponds to the procedure Herodotus described as being performed for the poorest ones, i.e. rinsing out the intestines and keeping the body in natron for 70 days. The remains of organs are well visible as well as those of resin that was used for rinsing out.



Mumija nepoznatog muškarca

Mumija je otkupljena u okviru Kollerove zbirke u dvostrukom drvenom sarkofagu žene Kareset, kćeri Padi-Ptaha iz ptolemejskog razdoblja (332. – 30. pr. Kr.). Sarkofag je oslikan uobičajenom ikonografijom i ispisanim zaštitničkim izrekama i nabrajanjem žrtava “duši gospodarice kuće Kareset”. Istraživanja pomoću digitalnog roentgen (RTG) aparata, kompjutorizirane tomografije (CT) i magnetske rezonancije (MR) provedena u KB Dubrava tijekom 2010. godine pokazala su da se radi o tijelu muške osobe, stare između 20 i 30 godina što je također potvrđeno i ekspertizom stručnjaka iz Instituta za antropologiju. Osim standardnih antropoloških kriterija za određivanje spola, falus koji je očuvan te se nalazi na svom anatomskom mjestu bio je nedvojbeno potvrda spolu mumije.

Kako bi se pobliže utvrdilo o kakvoj se mumiji radi obavljen je i test datiranja C14, kojim je mumija smještena između 800. i 840. godine prije Krista. Time je potvrđeno da mumija ne pripada sarkofagu od kojeg je starija čak oko 500 godina. Mumija nepoznatog muškarca pruža uvid u tehnologiju mumificiranja u vrijeme trećeg prijelaznog razdoblja, kada mumificiranje doseže svoj vrhunac, što je i potvrđeno usporedbom ove mumije s ostalim zagrebačkim mumijama. Naime, unutarnji organi najprije su izvađeni iz tijela, potom zasebno mumificirani i omotani lanenim trakama u četiri “paketa”, koji zamjenjuju kanope iz ranijih razdoblja, te na kraju vraćeni u torakalnu i abdominalnu šupljinu. Ruke su prekrížene na prsištu. U ovom periodu balzameri su pokušavali učiniti mumije što sličnije tijelu za života te su kroz više rezova punjene lanenim elementima, piljevinom, pijeskom i blatom kako bi se tijela što bolje uobličila. To se vrlo dobro uočava i na mumiji nepoznatog muškarca. Abdominalni rez kroz koji je izvršena evisceracija jasno se vidi u lijevom donjem abdomenu koji je nakon završenog procesa “začepljen” gore opisanim materijalima. Posebnost ove mumije je da je nedvojbeno utvrđen uzrok smrti. Uočene su brojne litičke lezije po cijelom skeletu; na kralježnici i na kostima lubanje što upućuje na neki tu-

Mummy of anonymous male

As part of Koller's collection the mummy was purchased in a double wooden sarcophagus of the wife Kareset, the daughter Padi-Ptah from the Ptolemaic Period (332 – 30 BC). The sarcophagus is painted with the common iconography and engraved with protection spells and containing a list of offerings “to the soul of the lady of the house of Kareset”. The research carried out with the help of digital X-rays (DR), computed tomography (CT) and magnetic resonance (MR) at Dubrava University Hospital during 2010 showed that this is the body of a male person between his 20s and 30s, which was also confirmed by the experts of the Institute of Anthropology. Apart from standard anthropologic criteria for defining gender, the preserved phallus positioned in its anatomic place was undoubtedly a confirmation of the mummy's sex.

In order to define more closely what kind of mummy it was, the carbon dating test C14 was performed, which dated the mummy back to 800 and 840 years BC. This confirmed the mummy did not belong to the sarcophagus in which it was found since it was about 500 years older than the sarcophagus itself. The mummy of the anonymous male provides an insight into the mummification technology at the time of the third transitory period when mummification reached its peak. This fact was confirmed by comparing this mummy to the other mummies of the Archaeological Museum in Zagreb. In that procedure, internal organs were first extracted from the body, separately mummified and wrapped in linen strips in four “packages” (that replaced canopic jars from the earlier periods) and were then returned into the thoracic and abdominal cavities. The arms were crossed on the chest. In this period, embalmers tried to make mummies look as similar as possible to the bodies of living persons, so that they packed them with linen, sawdust, sand and mud through numerous cuts, in order to shape the body as well as they could. This practice can be easily identified also on the mummy of the anonymous

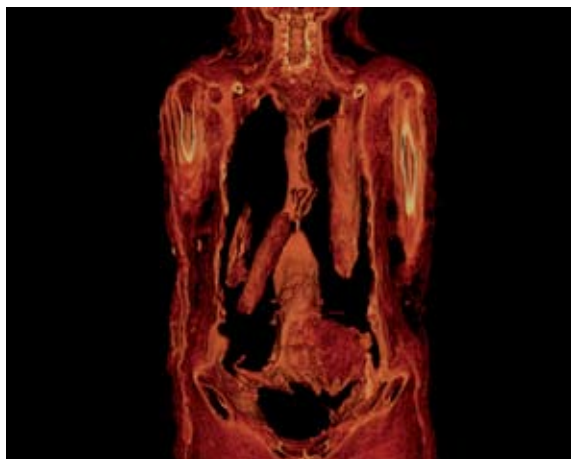
morski proces. Na mumiji nepoznatog muškarca tehnika magnetske rezonancije (MR) prvi put u svijetu uspješno je upotrijebljena u svrhu diferencijalne dijagnoze, što s ostalim metodama nije bilo moguće. Signal magnetske rezonancije dehidriranih tkiva je vrlo teško dobiti, no tkiva bogata kolagenom mogu dati dobar signal. Najbolji primjer su intervertebralni diskovi koji se lošije vide metodama koje koriste RTG zrake (CT i RTG), a na ovoj mumiji bili su u potpunosti očuvani. To je isključilo mogućnost neke upalne (infektivne) bolesti i suzilo dijagnozu na histiocitozu Langerhansovih stanica, multipli mijelom ili metastaze. S obzirom na raspored lezija, na dob te spol mumije, ponajprije se radi o Hand-Schueller-Christianovoj bolesti, podvrsti histiocitoze Langerhansovih stanica. Tu se radi o nekontroliranom umnažanju Langerhansovih stanica, stanica imunskog sustava koje potječu iz koštane srži te kasnije migriraju u kožu i limfne čvorove. Nekontroliranim umnažanjem nadomještaju normalnu strukturu kosti i mekih tkiva te ih vidimo kao litičke lezije. Kod oblika bolesti koji se naziva Hand-Schueller-Christianova bolest često je zahvaćena *sella turcica*, koštano "sedlo" u kojem se nalazi hipofiza, endokrina žlijezda koja svojim hormonima regulira homeostazu organizma što dovodi do poremećaja funkcije hipofize i dijabetesa insipidusa. Kao posljedica zahvaćenosti kostiju orbite, javlja se egzoftalmus (izbočenje očnih jabučica) koji može dovesti i do sljepoće. Promijenjene stanice zahvaćaju i ostale kosti glave kao i kralježnicu. Upravo ovakav raspored lezija na proučavanoj mumiji upućuje na dijagnozu koja mora da je za "pacijenta" iz 22. dinastije bila u početku neugodna, osip i svrbež na koži te dijabetes, a kasnije i vrlo bolna te deformirajuća (defekt frontalne kosti kao i orbitalnog zida).

male. The abdominal cut through which evisceration was performed can be clearly seen on the left lower abdomen. Once the process was completed, the cut was "plugged" with the abovementioned materials. What is peculiar about this mummy is its undoubtedly identified cause of death. Numerous lytic lesions on the whole skeleton, the spine and skull bones indicate a process of tumour growth. On the mummy of the anonymous male the technique of magnetic resonance (MR) was successfully used for the first time in the world with the purpose of differential diagnosis – something that was impossible to obtain with other methods. Magnetic resonance signals can be hardly obtained from dehydrated tissues, but tissues rich in collagen may provide a good signal. The best examples are intervertebral disks that can be poorly seen when using X-rays (CT and RTG), and on this mummy they were entirely preserved. This excluded the possibility of an infectious disease and narrowed the diagnosis to Langerhans cell histiocytosis, multiple myeloma or a metastatic disease. Based on the arrangement of lesions, the age and sex of the mummy, this was primarily diagnosed as Hand-Schueller-Christian disease, a sub-category of Langerhans cell histiocytosis. This disorder causes the uncontrolled proliferation of Langerhans cells, the cells of the immune system that migrate from the bone marrow into the skin and lymph nodes. By means of uncontrolled proliferation they replace the normal structure of bones and soft tissues, which accounts for the fact that we see them as lytic lesions. In the form of the disease known as Hand-Schueller-Christian disease, the sellar region of the sphenoid bone is often involved, in which the pituitary is positioned (the endocrinal gland in charge of regulating with its hormones the body homeostasis), causing thereby the dysfunction of the pituitary and leading to diabetes insipidus. As a consequence of the involvement of orbital bones, also exophthalmos appears (protrusion of eye bulbs) which may lead to blindness. The changed cells proliferate also into other skull bones and into the spine. Exactly such an arrangement of lesions

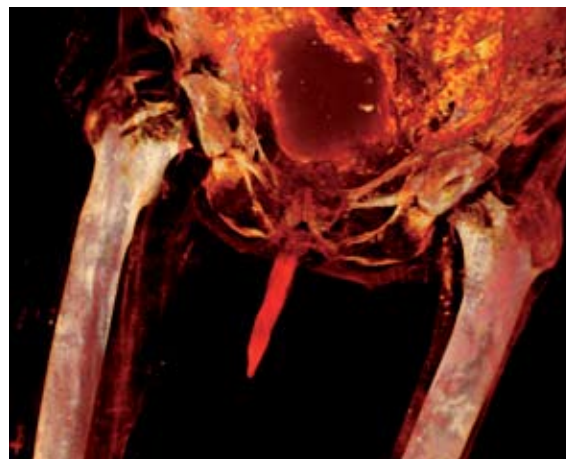CT VRT rekonstrukcija toraksa i abdomena pokazuje vraćene organe u tijelo
CT VRT reconstruction of thorax and abdomen showing organs placed in body

CT VRT rekonstrukcija nedvojbeno pokazuje o kojem se spolu radi

CT VRT reconstruction indisputably indicates the mummy's sex



on the examined mummy indicates a diagnosis that must have been at first unpleasant for that 22nd dynasty "patient" suffering from rash, itching of the skin and diabetes, only to become very painful and deforming (frontal bone defect and defect of the orbital wall) in a later stage.



Mumija Kaipamau

U kartonaži obojenoj svijetlim žutim i zelenim tonovima sačuvana je mumija žene Kaipamau kao i mumija nepoznatog muškarca iz 22. dinastije (945. – 715. pr. Kr.). Ona je u zagrebački muzej pristigla 1970. godine u znak zahvale Arapske Republike Egipat za sudjelovanje poduzeća i stručnjaka s područja bivše države u UNESCO-voj akciji spašavanja spomenika u Nubiji, nakon što je puštena u promet hidrocentrala južno od Asuana. Sarkofag je pronađen u El-Asasifu na zapadnoj obali Luksora u grobu Kheruefa (TT 192). Riječ je o ženi iz obitelji Amonovih svećenika, koja je za ukope svojih članova ponovno upotrijebila grobnicu iz 18. dinastije. Mumija Amonove pjevačice imena Kaipamau, obložena je bogato oslikanom kartonažom. Ikonografija kartonaže bogata je i tipična za razdoblje nastanka spomenika. Na prsima vidimo pticu – simbol duše koja se oslobađa iz tijela, ali i solarnog božanstva. Krila ptice raširena su, na glavi nosi *ureus*, a u kandžama drži simbole života *ankh*. Prevladavaju žuti tonovi, a sa

The Kaipamau mummy

In the cartonnage painted in light yellow and green nuances, the mummy of the woman Kaipamau was preserved as well as the mummy of an anonymous male from the 22nd dynasty (945 – 715 BC). She was brought to the Zagreb Museum in 1970 as a sign of gratitude expressed by the Arabic Republic of Egypt to the former Yugoslavia for its participation with enterprises and experts in UNESCO's actions for saving the monuments in Nubia, after the hydro-electric power plant started operating south of Asuan. The sarcophagus was found in El-Asasif on the west coast of Luxor in the grave of Kheruef (TT 192). It was a woman from the family of Amon's priests that used the tomb of the 18th dynasty for burying their family members.

The mummy of Amon's singer named Kaipamau is covered with nicely painted cartonnage. The iconography of the cartonnage is rich and typical of the period in which the monument appeared. A bird is depicted on the chest as a symbol of the soul being freed

dviju strana fetiša iz Abidosa, koji se proteže sredinom donjega dijela tijela, prikazane su Izida i Neftida. Dvije se božice pojavljuju kao žene s krilima i kao dvije sokolice. Na prsima nalazi se sokolski bog raširenih krila, a sa dviju strana u visini nadlaktica su sa svake strane po dva od četiri Horusova sina.

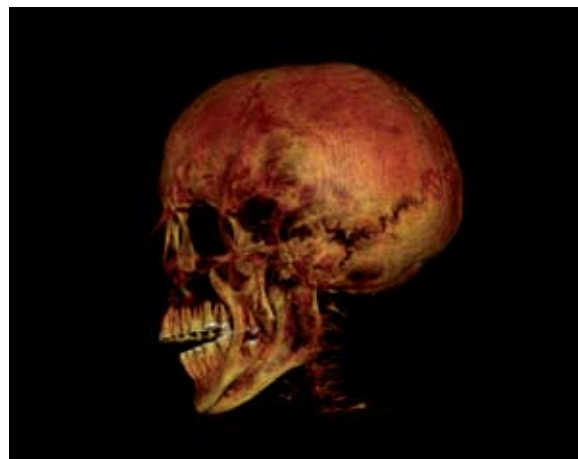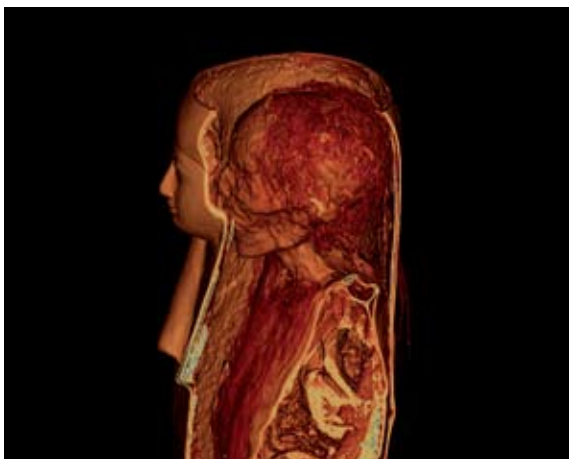
Mozak je izvađen transnazalno, a u lubanji se vide ostatci ricinusa, no ne i ostatci mozgovine ili moždanih ovojnica. Očne duplje su ispunjene kao i oralna šupljina, no nema staklenih očiju. Evisceracija je, čini se, provedena jer se jasno vidi abdominalni rez na lijevoj strani no obilni ostatci organa zbušnjaju te navode na zaključak da je mumifikacija izvedena ili na brzinu ili nekvalitetno, moguće zbog manjka financijskih sredstava pokojnice.

of the body but also as the symbol of a solar deity. The bird's wings are out-spread, it carries an *ureus* on the head, and in the clutches the symbols of life *ankh*. Yellow nuances prevail and from two sides of the fetish from Abidos, that runs in the middle of the lower part of the body, Isis and Nephthys are depicted. The two goddesses are represented as women with wings and as two female falcons. On the chest the falcon god with out-spread wings is depicted, and on the two sides at the level of the upper arms on each side there are two of the four sons of Horus.

The brain was extracted trans-nasally, and in the skull remains of resin like fluid were found but no remains of meningeae or brain-matter. Orbital cavities were packed as well as the oral cavity but there were no glass eyes. The evisceration was apparently carried out since the cut on the left side is clearly visible. What is confusing are the large remains of organs that lead to the conclusion that the mummification was performed either in a rush or not adequately, maybe due to lack of financial resources of the deceased person.



CT VRT rekonstrukcije
CT VRT reconstructions



Peta mumija

Takozvana "Peta mumija" anonimne ženske osobe dar je biskupa zagrebačkog Jurja Haulika Narodnom muzeju u 19. stoljeću. Godinama je bila pohranjena u depou Muzeja, a javnosti je prvi put prikazana u okviru male izložbe *Tajne egipatskih mumija* 2010. godine. Ona je bila položena u sarkofag koji se na prvi pogled prepoznaje kao neautentičan, i koji je najvjerojatnije nastao u vrijeme europskog pokreta iz 19. stoljeća takozvane "egiptomanije". Tada se, zahvaljujući fascinaciji Egiptom pri izradi namještaja, gradnji, pa čak i pri izradi sarkofaga i grobnica, često imitiralo produkte staroegipatske umjetnosti. Zbog sumnje u autentičnost mumije i zbog neobičnog izgleda sarkofaga obavljeno je testiranje pomoću C14. To istraživanje je pokazalo datiranje u 4. st. pr. Kr. Iz toga se moglo zaključiti da je mumija pohranjena u taj lijes autentična. Nakon utvrđivanja te činjenice na mumiji su započela razna istraživanja u organizaciji Instituta za antropologiju i Kliničke bolnice Dubrava. Mumija je snimana RTG-om i CT-om kako bi se pokazala njezina struktura i otkrili detalji o tijelu. Istraživanja su donijela konačnu potvrdu da je riječ o produktu iz starog Egipta. Jasno se moglo vidjeti kako je mozak uklonjen kroz nosnu šupljinu. Pri tome se koristila drvena grana (letvica), komadić koje je ostao u kranijalnoj šupljini. Zanimljivost je da je na ovoj mumiji prvi put u svijetu izvršena endoskopija pod nadzorom CT-a prilikom koje je kirurškim instrumentom endoskopom izvađena grančica koja je poslana na analizu na Šumarski fakultet Sveučilišta u Zagrebu gdje je ustanovljeno da se radi o drvu bambusa. Time je dobiven neposredan dokaz da su se stari Egipćani koristili i drvenim instrumentima prilikom vađenja mozga. Serijom eksperimenata 90-ih godina u Njemačkoj dokazano je da je vrlo jednostavno probiti kroz nos put u lubanju upravo bambusovim štapom i mehaničkim pokretima pretvoriti mozak u tekuću kašu, koja nakon okretanja tijela na trbuh vrlo lako "iscuri". Zanimljivo je da Herodot spominje samo metalnu kuku s kojom se vadio mozak, iako on opisuje samo "zamrznuti" trenutak u dugoj povijesti mumifikacije, ipak je ovaj podatak vrlo znača-

The Fifth Mummy

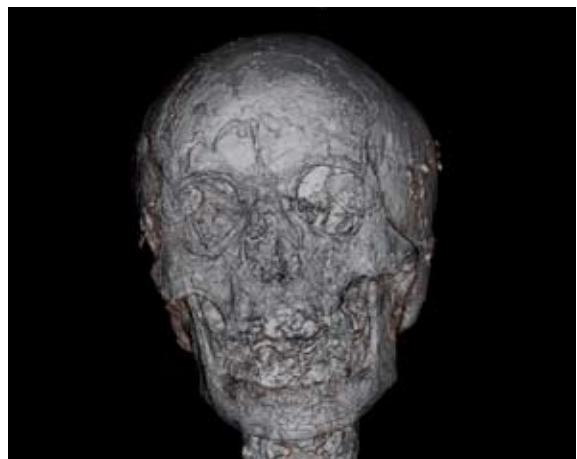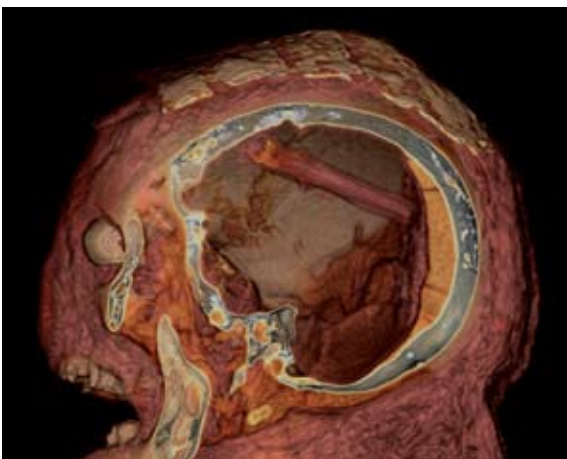
The so-called "Fifth Mummy" of an anonymous female person is the gift of the Zagreb bishop Juraj Haulik to the Land's Museum in the 19th century. The mummy was stored in the museum's depot for years, and was exhibited to the public for the first time within the small 2010 exhibition *The Secrets of Egyptian Mummies*. She was deposited in a sarcophagus which was immediately recognised as non-authentic and made most likely during the so-called period of "Egypt-mania" - a European movement of the 19th century. At that time, thanks to the fascination with Egypt, when making furniture, building and even in the making of sarcophagi and tombs, the products of ancient Egyptian art were imitated. To exclude all possibility of doubt concerning the authenticity of the mummy and the unusual appearance of the sarcophagus, a C14 testing was carried out. This technique dated the mummy back to the 4th century BC, proving thus that the mummy placed in that sarcophagus was authentic. After establishing that fact, various examinations took place organised by the Institute of Anthropology and the Dubrava University Hospital. The mummy was subject to X-rays and a CT, in order to see its structure and discover details about the body. Examinations provided final confirmation of the fact that it was a product of Ancient Egypt. It could be clearly seen how the brain was extracted through the nasal cavity. In doing so a wooden branch was used whose small part remained in the cranial fossa. The interesting thing about this mummy is the fact that this was the first time in the world that an endoscopy was performed under CT guided endoscopy in the course of which a little branch was extracted with a surgical instrument, the endoscope. The branch was then sent for analysis to the Faculty of Forestry of the University in Zagreb that identified it as being a bamboo. Thereby a direct proof was provided of the fact that ancient Egyptians used wooden instruments when extracting the brain. By means of a series of experiments in the 1990s it was proved in Germany that making one's way through the nose into the skull was very simple exactly by

jan za upotpunjavanje slike o mumifikaciji. Toraks i abdomen su eviscerirani i ispunjeni lanenim elementima kao i smolom. Naziru se ostatci zamotanih organa što je bio nedvojbena dokaz o autentičnosti. Ruke su prekrížene na prsištu. Osteoartitičke promjene kao i ostali antropološki podatci govore u prilog da se radi o osobi između 30 i 40 godina (bliže 40-ima) te da je za vrijeme života pretrpjela prijelom obje kosti podlaktice koje se gotovo uvijek klasificiraju kao obrambene, a koje su zacijelile s minimalnom angulacijom tijekom života. Mumija je u dosta lošem stanju, sa dvije velike rupe vidljive i golim okom na trbuhu i leđima. Na RTG-u i CT-u vidi se metalni artefakt u obliku šipke duljine od oko 1 metar, koja se proteže od ošita prema niže te je na tri mjesta ojačana kako bi povezala noge s tijelom. Koštani zdjelčni obruč izuzetno je oštećen, *post mortem*, kao i obje natkoljениčne kosti koje su luksirane (nisu uložene u čašice zgloba kuka) u kuku. Neobični nalaz je najvjerojatnije djelo trgovaca umjetninama iz 19. stoljeća koji su htjeli “učvrstiti” statu ru mumije te su je u tom poboljšanom stanju prodali nadbiskupu Hauliku.

means of a bamboo stick, turning the brain by mechanical movements into a liquid, so that once the body had been turned on the belly, it “was poured out” very easily. Interestingly, Herodotus mentioned only a metal hook used to remove the brain. Although he described only a “frozen” moment in the history of mummification, this piece of data is still very important for getting the whole picture of mummification. The thorax and abdomen were eviscerated and packed with linen elements and resin. The remains of enwrapped organs could be discerned providing a doubtless proof of authenticity. The hands are crossed on the chest. Osteoarthritic changes as well as other anthropologic data confirm the fact that this person was between her 30s and 40s (closer to her 40s) and that during her lifetime she suffered from a fracture of both lower arms, which are always associated with defence actions that healed up with minimal angulations in her lifetime. The mummy is in a very bad shape, with two large holes on the abdomen and on the back that are visible to the naked eye. Both X-rays-examination and CT revealed a metal artefact in the form of a bar that is approximately 1m long and runs from the diaphragm downwards and is fortified in three places in order to connect the legs to the body. The pelvis was seriously damaged post mortally and both thigh bones are luxated (are not inserted into the cup of the hip joint) in the hip. This unusual finding is most likely the work of 19th century art dealers who wanted to “fix” the mummy and once they improved its condition, they sold it to archbishop Haulik.

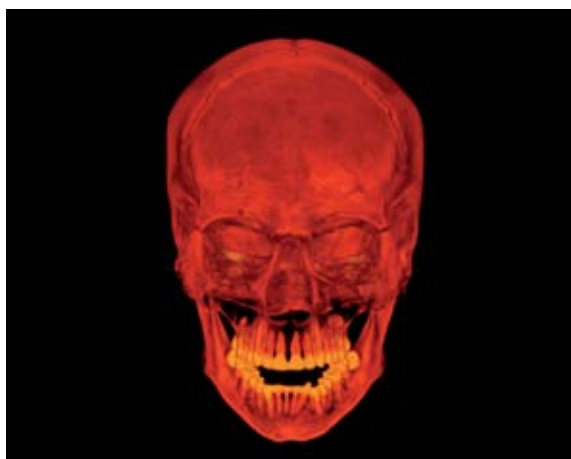
CT “Pete mumije”

CT of the “Fifth Mummy”



Mumificirani dijelovi ljudskih tijela

Zbirka sadrži i mumificirane dijelove tijela; četiri šake (dosad se sumnjalo da su dvije životinjskog podrijetla), dva stopala i dvije glave. Mozak je izvađen transnazalno u obje lubanje, no po ostalom se dosta razlikuju. Glava 02 je glava odraslog muškarca, a lice je prekriveno smjesom nalik na smolu, koja, međutim, ne daje visok intenzitet signala na magnetskoj rezonanciji kao smole, koje ima u izobilju u stražnjoj lubanjskoj jami, što daje naslutiti da se ne radi o istom materijalu. Moguće da je služila za pričvršćivanje poveza oko glave kojih više nema. Zanimljivost je i prodor smole u mastoidne celule. Vidi se i dosta ostataka mozgovine ili moždanih ovojnica u lubanjskoj šupljini kao i ostataka očnih struktura unutar orbita. Glava 01 je glava žene od oko 20 godina omotana ovojima iz kojih jasno izvire umjetni nos. Između vanjskih ovoja i glave vidi se smjesa raznih smola, koja se razlikuje od smole na prethodnoj glavi svojom gustoćom na CT-u i intenzitetom na MR-u. Ovdje se intenzitet podudara s intenzitetom smole u stražnjoj lubanjskoj jami koje nema previše. Objе lubanje imaju prognatizam gornje čeljusti. Šake i stopala su svakako dijelovi tijela odraslih osoba, bez vidljivih patoloških procesa, fraktura ili degenerativnih promjena. Nisu omotane povojima i vidi se sloj mumificirane kože, koja je premazana, ovisno o uzorku, različitim količinama smole.

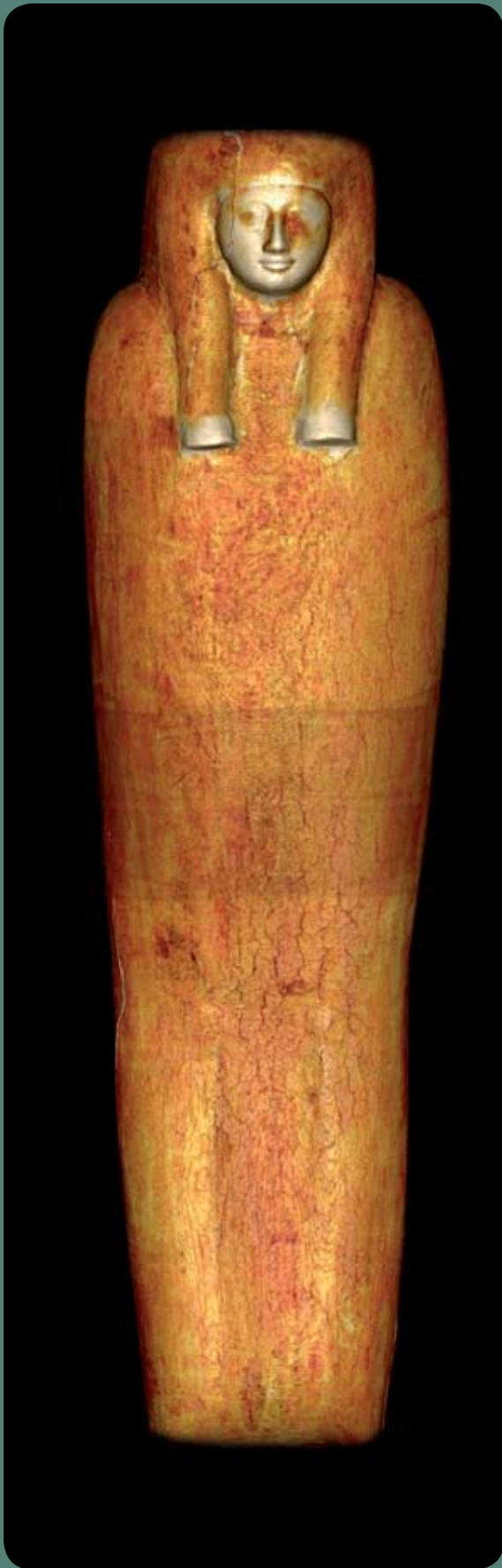

Mummified parts of human bodies

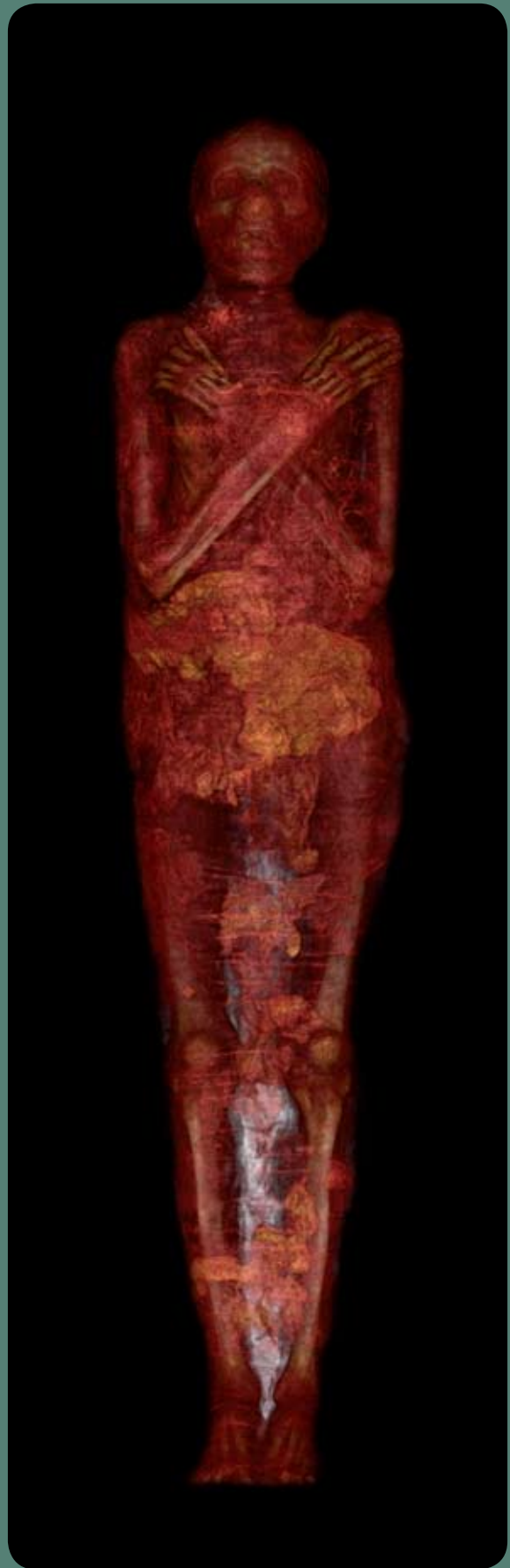The collection contains parts of the body: four fists (two of them were considered to be of animal origin), two feet and two heads. The brain was extracted transnasally in both skulls, but they present numerous differences when it comes to other aspects. Head 02 is of an adult male, whose face is covered with a mixture similar to resin, which however does not produce a high intensity signal on magnetic resonance as resin, which are abundantly present in the posterior cranial fossa, showing that these are not the same materials. This mixture might have served to fix the strips around the head that are no longer there. What is also interesting about this exhibit is the penetration of resin into mastoid cells. Furthermore, there are many remains of brainmatter or meningae in the skull fossa and eye structures within the orbital cavities. Head 01 is that of a woman in her 20s, enwrapped in strips from which an artificial nose stands out clearly. Between the outer bandages and the head there is a mixture of various resins different from those found in head 02 in terms of density on the CT and intensity on the MR scanings. In head 01 the intensity coincides with that of the little amount of resin found on the posterior cervical fossa. In both skulls maxillary prognatism can be observed. Fists and feet are certainly parts of the body of adults, without visible pathological processes, fractures or degenerative changes. They are not wrapped in strips so that a layer of mummified skin can be seen, which is smeared with different quantities of resin depending on the pattern.

CT VRT rekonstrukcija glave odraslog muškarca

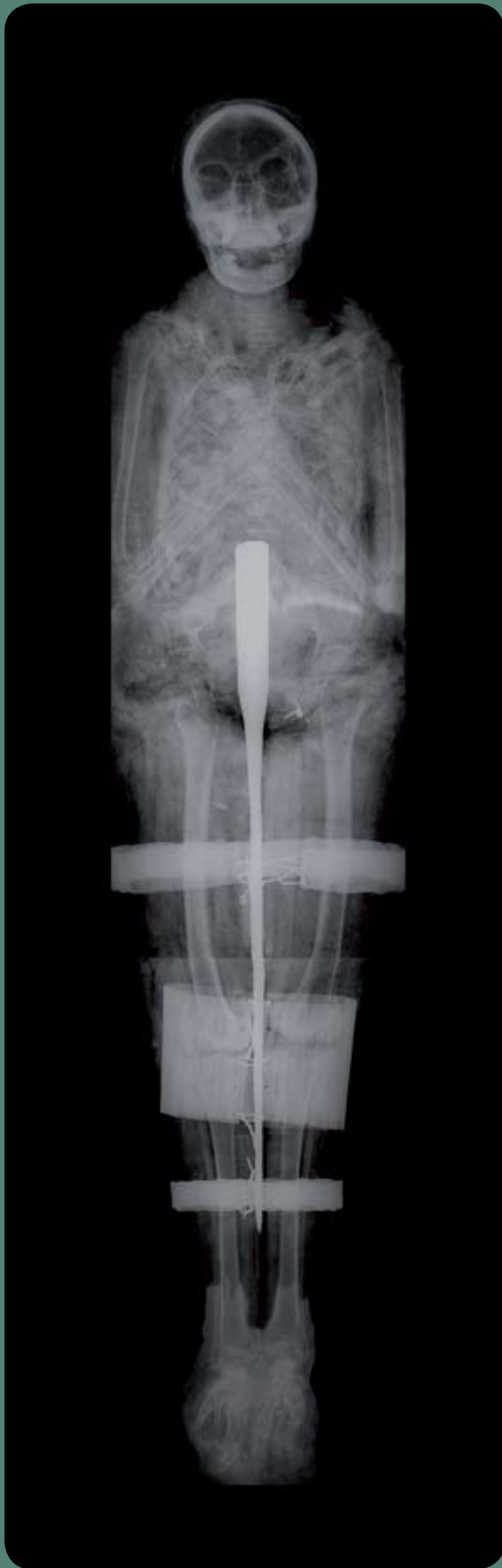CT VRT reconstruction of the head of the adult male



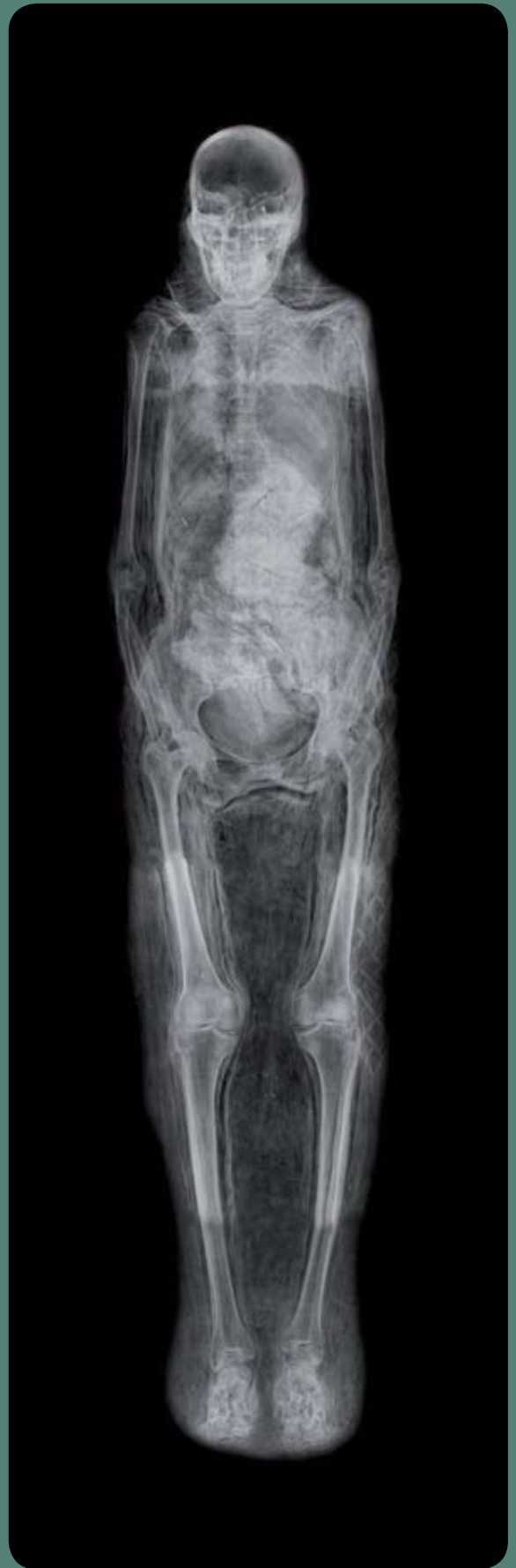CT VRT rekonstrukcija mumije Kaipamau
CT VRT reconstruction of the Kaipamau mummy



CT VRT rekonstr. mumije nepoznatog muškarca
CT VRT reconstr. of the unknown male mummy



RTG "Pete" zagrebačke mumiije
X-ray of "Fifth" Zagreb mummy



RTG mumiije Šepenun
X-ray of the Shepenun mummy



Cavka M, Jankovic I, Rajic Sikanjic P, Ticinovic N, Rados S, Ivanac G, Brkljacic B. Insights into a Mummy: A Paleoradiological Analysis. *Coll Antropol.* 2010;34:797–802.

Cavka M, Petaros A, Ivanac G, Aganovic L, Jankovic I, Reiter G, Speier P, Nielles-Vallespin S, Brkljacic B. An ancient disease enclosed in somebody else's tomb: a mystery revealed 3000 year later by CT and MR investigation of a dry mummy. *Coll Antropol.* 2012;36:281-6.

Cavka M, Petaros A, Boscic D, Kavur L, Jankovic I, Despot R, Trajkovic J, Brkljacic B. CT guided endoscopic recovery of a foreign object from the cranial cavity of an ancient Egyptian mummy. *Radiographics.* 2012 nov. In press

Chhem RK, Brothwell DR. *Paleoradiology.* Berlin Heidelberg: Springer-Verlag; 2008.

Cosmacini P, Piacentini P. Notes on the history of the radiological study of Egyptian mummies: from X-rays to new imaging techniques. *Radiol med.* 2008;113:615-26.

Dannenfeldt KH. Egyptian mumia: the sixteenth century experience and debat. *Sixt Century J.* 1985;16:163–180.

Hawass Z, Gad YZ, Ismail S, Khairat R, Fathalla D, Hasan N i sur. Ancestry and pathology in King Tutankhamun's family. *JAMA.* 2010;303:638-47.

Herodot. *The history of Herodotus.* Project Gutenberg; 2001.

Ikram S, Dodson A. *The mummy in Ancient Egypt equipping the dead for eternity.* London: Thames and Hudson Ltd; 1998.

Kelava, T, Cavka, M. Akhenaten, a unique pharaoh. *South African Medical Journal.* 2012; 102(2):58.

Lynnerup N. Mummies. *Am J Phys Anthropol.* 2007;Suppl 45:162-90.

Notman DN, Anderson L, Beattie OB, Amy R. Arctic paleoradiology: portable radiographic examination of two frozen sailors from the Franklin expedition (1845-1848). *AJR Am J Roentgenol.* 1987;149:347-50.

Pommerening T. *Mummification Techniques and the Cult of the Dead in Ancient Egypt – A Chronological Overview.* U: Wieczorek A, Rosendahl W, urednici. *Mummies of the world.* Muenchen, Berlin, London, New York: Prestel Verlag; 2010.

Rühli FJ, von Waldburg H, Nielles-Vallespin S, Böni T, Speier P. Clinical magnetic resonance imaging of ancient dry human mummies without rehydration. *JAMA.* 2007;298:2618-20.

Uranić I. *Aegyptiaca Zagrabienisia : Egipatska zbirka Arheološkog muzeja u Zagrebu. = Egyptian Collection of the Archaeological Museum in Zagreb.* Zagreb: Arheološki muzej; 2007.

Mumije životinja

Animal mummies

Životinjske mumije u drevnome Egiptu

Tradicija mumificiranja životinja u drevnome Egiptu bila jednako tako popularna i rasprostranjena kao i ona ljudi. Egipatske životinjske mumije, s obzirom na način mumificiranja, mogu se podijeliti u dvije osnovne kategorije: (I.) prirodno i (II.) artifičijelno (antropogeno) mumificirane životinje. Prirodno mumificirane životinje produkt su povoljnih okolišnih uvjeta egipatskoga područja koji, djelujući na tijela uginulih životinja, sprječavaju da ista podlegnu nepovratnom procesu raspadanja. Suha klima, dugotrajna ekspozicija suncu, visoka temperatura i porozno pješčano tlo koje olakšava brzo dreniranje tjelesnih sokova, dovode do isušavanja tijela životinja i posljedičnog očuvanja mekotivnih struktura, odnosno do prirodne mumifikacije. Brojni muzeji u svijetu čuvaju primjere prirodnim putem savršeno očuvanih životinjskih tijela, koja obuhvaćaju pripadnike svih životinjskih razreda. Vjeruje se da je upravo doticaj s prirodno mumificiranim tijelima potaknuo Egipćane da počinju

Animal mummies in Ancient Egypt

The tradition of animal mummification in Ancient Egypt was as popular and widespread as that of humans. In terms of the manner of mummification, Egyptian animal mummies may be divided into two basic categories: (I) naturally and (II) artificially (anthropogenically) mummified animals. Naturally mummified animals were the result of favourable environmental conditions typical of the Egyptian area, which affected the bodies of dead animals preventing their progressive decay. Dry climate, long-lasting sun exposure, high temperature and porous sand soil, which facilitates drainage of body liquids, made animal bodies dry and consequently preserved soft tissue structures, leading to natural mummification. Numerous museums in the world display exhibits of naturally perfectly preserved animal bodies including representatives of all animal species. It is believed that the contact with naturally mummified bodies triggered Egyptians to start a new tradition of anthropogenic/artificial mummification.

razvijati tradiciju antropogene/artificijelne mumifikacije ljudi i životinja. Sam način mumifikacije i razlozi koji su doveli do mumifikacije ljudi i životinja u Egiptu, međusobno su se razlikovali.

Iako danas postoje brojni sačuvani primjeri artificijelno mumificiranih životinja koji bi svojim brojem mogli nadmašiti one ljudskih mumija, tradicija mumifikacije životinja kasnila je za onom ljudi. Razlog tome bio je, s jedne strane, ekonomske prirode - diktiran skupoćom samog procesa mumifikacije, a s druge strane religijske prirode - trend mumifikacije životinja blisko je pratio dinamiku širenja kultova životinja koji su dosegli svoj vrhunac u Kasnom periodu drevnoga Egipta (664.-332. pr. Kr.). Ipak, prvi izolirani primjeri mumificiranih životinja zabilježeni su već u preddinastijskom razdoblju (5500.-4000. pr. Kr.).

Osim vremena u kojemu se provodila, mumifikacija ljudi i životinja razlikovala se i s obzirom na razloge koji su je potakli. Dok se mumifikacija ljudi smatrala neophodnom za očuvanje duše nakon smrti, mumifikacija životinja bila je potaknuta drugačijim potrebama. Osnovni razlog mumificiranja životinja u drevnom Egiptu može se pripisati ukorijenjenoj ljudskoj potrebi za formiranjem kultova i slavljenjem božanstava. Egipćani su tako koristili životinjske mumije kao votive te su ih nerijetko prinosili kao žrtvene poklone svojim božanstvima.

S druge strane, Egipćani su pojedinim životinjskim vrstama pripisivali puno značajniju ulogu te ih poistovjećivali s egipatskim bogovima. S obzirom na to da je egipatska mitologija bliska kultu štovanja životinja, većina njihovih božanstava prikazivala se u formi životinja ili poluživotinja-poluljudi. Među njima najistaknutiji su bili bog Apis (bik), božica Bastet (mačka), Thoth (ibis, pavijan), Sobek (krokodil) te Anubis (pas, šakal). Nabrojene životinjske vrste smatrane su zemaljskim utjelovljenjem pripadajućih božanstava te su, prema tome, bile obožavane i zaštićene, a ujedno im je pripadalo pravo na lagan, dug život i prirodnu smrt. Egipćani su ih slavili jednako kao i svoja božanstva.

However, the reasons that led to mummification and the ways in which it was performed were different for humans and for animals.

Although there are many preserved examples of artificially mummified animals, which could exceed the number of human mummies, the tradition of animal mummification lagged behind that of humans. This can be attributed both to economic (expensiveness of the mummification process itself) and religious reasons. In fact, mummification of animals was closely related to animal cults that spread throughout Egypt and reached its peak in the late period (664-332 BC). Still, first isolated examples of mummified animals had been already recorded in the Predynastic Period (5500-4000 BC).

Alongside the time when it was carried out, human and animal mummification differed also in respect of the reasons that motivated such mummification. While human mummification was considered indispensable for the soul to be saved after death, animal mummification was motivated by different needs. The major reason for animal mummification in Ancient Egypt may be attributed to the rooted human need to form cults and worship gods. Hence, the Egyptians used animal mummies as votive offerings that were often sacrificed to their gods.

On the other hand, Egyptians attributed to some animal species a much more significant role and equated them with Egyptian gods. Since the Egyptian mythology was closely related to the cult of worshipping animals, the majority of their deities were represented in the form of animals or half-animals and half-humans. Among them, the most prominent were the god Apis (bull), goddess Bastet (cat), Thoth (ibis, baboon), Sobek (crocodile) and Anubis (dog, jackal). The listed animal species were considered as earthly embodiments of the equivalent deities and were thus worshipped and protected and they automatically were entitled to a long life of leisure and natural death. Egyptians praised them as much as they worshipped their deities.

S obzirom na postojeće razlike u ulogama koje su Egipćani pripisivali različitim životinjskim vrstama, artifičijelno mumificirane životinje mogu se podijeliti u četiri osnovne grupe:

- a) Mumije životinja koje su predstavljale hranu za pokojnika te su se, zajedno s njime, zakapale u grobnicu
- b) Mumije životinja koje su imale ulogu kućnih ljubimaca te su zakapane zajedno s pokojnim vlasnikom
- c) Mumije životinja koje su prinošene kao žrtve (votivi) različitim božanstvima
- d) Mumije životinja koje su smatrane svetima i prema kojima su Egipćani gajili totemistički odnos

Sudbina životinja razlikovala se ovisno o tome kojem su vremenu i kojoj od kategorija pripadale. Tako su u četrnaestom stoljeću prije Krista, životinje najčešće bile zakapane kao kućni ljubimci koji su pratili svoje vlasnike na drugi svijet, u periodu između 945.-715. god. pr. Kr. (XXII. dinastija) bile su učestalije štovane kao svete, a tek je između 332. i 30. pr. Kr. počela njihova namjenska proizvodnja kao žrtvenih votivskih objekata. Životinje posvećene određenim kultovima iz doba XXII. dinastije mumificirale su se tek nakon njihove prirodne smrti, a one koje su imale ulogu žrtvenih votiva bile su najčešće ubijene još kao mladunci. Zbog ljudske potrebe da što više ugodi božanstvima, produkcija votivskih mumija u kasnijim egipatskim periodima prerasla je u značajan biznis, pri čemu su se mumije životinja prodavale hodočasnici na njihovom putu do nekropola. Sama potreba za životinjskim votivima često je nadmašila mogućnosti njihove produkcije. Tome govori u prilog podatak da je tijekom 19. stoljeća jedna poljoprivredna tvrtka otkupila čak 180.000 mačjih mumija, što je zapravo predstavljalo tek jedan mali dio cjelokupnog nasljeđa mumificiranih tijela porijeklom iz drevnog Egipta. To je u jednom trenutku pokrenulo značajnu proizvodnju lažnih mumija. Slično kao što je u srednjem vijeku započela hiperprodukcija svetačkih relikvija od kojih su brojne bile neautentične, tako je u drevnome Egiptu stvorena masovna trgovina životinjskim mumijama, od

On the basis of the different roles Egyptians attributed to different animal species, artificially mummified animals can be divided into four basic categories:

- a) Mummies of animals that were perceived as food for the deceased and were thus buried together with the dead person in the tomb
- b) Mummies of animals that had the role of pets and were buried together with the deceased owner
- c) Mummies of animals that were sacrificed to different deities (votive offerings)
- d) Mummies of animals that were considered sacred and served as totems

The fate of animals depended on the fact to which period and category they belonged. Hence, in the 14th century BC animals were mostly buried as pets accompanying their owners into the other world. In the period between 945-715 BC (XXII dynasty) animals were most often worshipped as sacred, and only in the period from 332 to 30 BC their designated production as sacrifice votive objects started. During the XXII dynasty, animals devoted to certain cults were mummified only after their natural death, while those who had the function of votive offerings were mostly killed as young. As a consequence of the human need to please the gods as much as possible, the production of votive mummies developed in later Egyptian periods into a major business with animal mummies being sold to pilgrims on their way to the necropolises. The need for votive offerings of animal mummies often exceeded the possibilities to produce them. This is also indicated by the fact that in the 19th century an agricultural company purchased as many as 180 000 cat mummies that represent only a small part of the overall heritage of mummified bodies originated from Ancient Egypt. At a certain moment this huge demand triggered the production of fake mummies. Similarly to the hyper-production of often unauthentic saints' relics in the Middle Ages, Ancient Egypt was characterized by mass trade in animal mummies that were not even of real animals.



kojih brojne nisu niti pripadale pravim životinjama. Proizvodnja lažnih mumija bila je puno brže i jeftinije rješenje za proizvođače mumija, a raspoznavanje lažnih mumija od onih pravih je, za običnog čovjeka, bilo gotovo nemoguće, s obzirom na to da se njihov vanjski izgled malokad razlikovao. Uostalom, i sama cijena mumificiranih votiva varirala je ovisno o brizi i vremenu posvećenom njihovoj mumifikaciji.

Mumije egipatskih životinja bile su najčešće mumificirane tako da su njihov vanjski oblik (forma smotuljka, kutija, sarkofag) i/ili prikaz životinje oslikan na zavoju, upućivali na to o kojoj se životinjskoj vrsti radi. Nažalost, do danas, brojne životinjske mumije su, dijelom zbog utjecaja vremena te dijelom zbog lošijeg i jeftinijeg načina mumificiranja, teško uspjele očuvati takvu prepoznatljivost. Ukoliko nije očuvan tipičan sarkofag/kutija u kojoj je životinja pohranjena, danas je teško raspoznati životinjsku vrstu isključivo temeljem oblika mumificiranog smotuljka. Reidentifikacija životinjskih mumija, kao i razlikovanje pravih mumija od lažnih kopija, bitan je korak u izučavanju povijesti i kulture mumificiranja drevnoga Egipta. Taj je proces u današnje vrijeme omogućen efikasnim iskorištavanjem modernih medicinskih slikovnih metoda.

Implementacija radiologije u znanstvenu analizu mumija pridonijela je razjašnjavanju brojnih segmenata života Egipćana (od načina života, bolesti od kojih su bolovali do uzroka smrti) i samog načina mumificiranja. Zbog toga se danas radiološka analiza mumificiranih tkiva smatra neizbježnim korakom u svakoj ozbiljnoj analizi ljudskih ili životinjskih mumija. Iako danas radiološka analiza ljudskih mumija itekako prednjači onoj životinja, zanimljivo je napomenuti da je prvo korištenje rendgenskih zraka u paleoradiološke svrhe, tek godinu dana nakon njihova otkrića (1896.), provedeno nad ostacima mumificirane životinje - mačke.

The production of fake animal mummies was a significantly faster and cheaper solution for mummy manufacturers. For a common person it was almost impossible to tell fake from real ones since their appearance rarely differed. After all, the very price of mummified votive animals varied depending on the care and time invested into their mummification. Mummies of Egyptian animals were mostly made so that their external form (the form of a wrap-up, a box, a sarcophagus) and/or the animal depicted on the bandages, indicated which animal species it contained. Regrettably, numerous mummies have not preserved that level of recognisability partly due to the impact of time and partly due to the poorer and cheaper mummification method employed.

If the typical box in which the animal was stored has not been preserved, it is very difficult today to tell the animal species solely on the basis of the form of the mummified wrap-up.

Re-identification of animal mummies as well as telling real from fake mummies is a major step in the study of history and culture of Ancient Egypt mummification. Today this process is made possible by using modern medical imaging methods. The implementation of radiology in the scientific analysis of mummies has contributed to clarifying numerous segments both in the life of Egyptians (from their lifestyle and the illnesses they suffered from to their cause of death) and the mummification method itself. Nowadays, radiologic analysis of mummified tissues represents an indispensable step in every serious analysis of both human and animal mummies. Although radiologic analysis of human mummies is leading the way compared to that of animal mummies, it is interesting to point out that the first use of X-rays for paleoradiological purposes, only a year after their discovery (1896), was conducted on the remains of a mummified animal – a cat.

Životinjske mumije Arheološkog muzeja u Zagrebu

Animal Mummies of The Archaeological Museum in Zagreb

U Arheološkom muzeju u Zagrebu čuva se nekoliko primjera životinjskih mumija i dijelova tijela za koje se smatralo da bi mogli pripadati životinjama. Analiza vanjskih karakteristika većeg dijela mumija nije dala dovoljno podataka da se zaključi o kojim se životinjskim vrstama radi. Prema tome, potvrđivanje inicijalnih pretpostavki i utvrđivanje autentičnosti mumija provedeno je na Zavodu za dijagnostičku i intervencijsku radiologiju Kliničke bolnice Dubrava, gdje je učinjena radiološka analiza ostataka. Nakon slikovne obradbe, uslijedilo je forenzičko-antropološko iščitavanje dobivenih radioloških snimaka. Specifičnost forenzičko-antropološke analize mumificiranih životinja leži u tome da je interpretacija slika često otežana zbog neprirodnog položaja i skvrčenosti tijela životinje što rezultira preklapanjem velikog broja anatomskih regija te zbog pratećih artefakata.

A few exemplars of animal mummies as well as bodily remains are believed to have belonged to animals and are stored at the Archaeological Museum in Zagreb. The analysis of the external features of most mummies has not provided enough information to allow the identification of the animal species in question. Therefore, actions performed to confirm initial presuppositions and to establish the authenticity of mummies have been entrusted to the Institute of Diagnostic and Intervention Radiology of the Dubrava Clinical Hospital, where the radiologic analysis of remains was conducted. Once the imaging process was completed, the forensic-anthropological examination of the obtained radiologic images followed. A peculiarity in the forensic-anthropological analysis of mummified animals lies in the fact that the interpretation of images is often complicated by the unnatural and cramped position of animals, causing a large number of anatomic regions to overlap, as well as by the presence of accompanying artefacts.

Mumificirani ostaci mačke

Vanjskim pregledom, prva analizirana mumija prezentira se kao amorfnu smotuljak tkanine i tkiva kroz koje prodiru kosti skvrčenog životinjskog tijela. Tek je radiološka analiza mumificirane životinje omogućila prepoznavanje kostura čiji su elementi ostali u prirodnom anatomskom odnosu. Radiološka analiza je potvrdila, bez sumnje, da se radi o ostacima mačke. Prednji dijelovi mačke (njezina glava, vrat, prednji ekstremiteti, prsni koš i dio kralježnice) nedostaju te su radiološkoj analizi bili dostupni tek rep, zdjelčni obruč, stražnji dio kralježnice i stražnji ekstremiteti. S obzirom na prisutnost osifikacijskih centara i još nedovršenu fuziju koštanih elemenata dostupnih analizi (pogotovo goljeničnih i metatarzalnih kosti) zaključuje se da ostaci pripadaju mladoj mački, dobi od oko 40-50 tjedana. Deartikulacija prednjeg i stražnjeg dijela tijela nastupila je vjerojatno uslijed rukovanja mumijom kroz vrijeme, s obzirom na to da se ne raspoznaju traumatske lezije na krajnjem segmentu kralježnice. Traumatske povrede, u vidu fraktura, uočavaju se na stražnjim ekstremitetima i obuhvaćaju obje bedrene kosti te desnu goljeničnu kost. Iako se, s obzirom na karakteristike samih fraktura, ne može isključiti da su iste prethodile smrti, njihov raspored, koji prati isti smjer u sve tri kosti, sugerira da je lom nastao kada se životinja već nalazila u dotičnom položaju. Najvjerojatnije su lomovi uslijedili prilikom nasilnog namještanja mačke u položaj u kojemu je mumificirana, odnosno postmortalno.

U ovom slučaju interpretacija traumatskih ozljeda bila je neophodna u analizi mumificiranih ostataka mačke, jer su brojne studije provedene na životinjskim mumijama, tek radiološkom pretragom, razotkrile neprirodni i nasilni tijek njihove smrti. Ipak, s obzirom na nedostatak prednjih dijelova tijela (pogotovo glave), ne može se sa sigurnošću isključiti mogućnost da je i "zagrebačka mačka", prije same mumifikacije ubijena.

Zagrebačka mumija mačke jedna je u nizu velikog broja mačaka mumificiranih tijekom stoljeća u drevnom Egiptu. Iako se, u rani-

Mummified cat remains

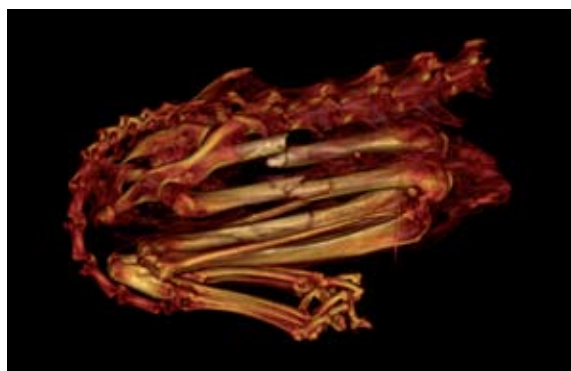
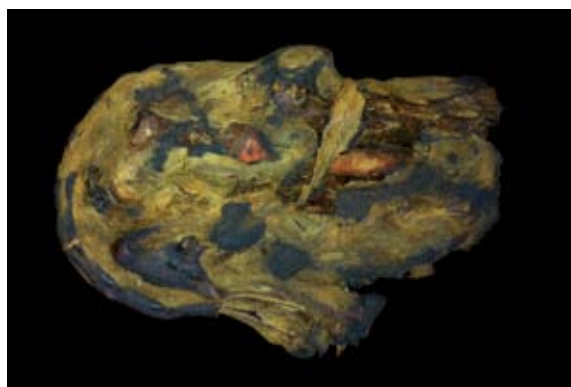
By means of external examination, the first analysed mummy appears as an amorphous bundle of linen and tissue pervaded with bones of a contracted animal body. It was only radiological examination of the mummified animal that enabled the recognition of the skeleton that still preserved its anatomical structure. Radiological analysis confirmed that the remains are that of a cat. The anterior parts of the cat (the head, neck, anterior extremities, chest and part of the spine) are missing so that only the tail, pelvis, the posterior part of the spine and the posterior extremities were available for radiological examination. Based on the presence of ossification centres and a still uncompleted fusion of bones (especially the tibia and metatarsal bones) it can be concluded that the remains belonged to a 40-50 weeks old cat. Disarticulation of the anterior and posterior parts of the body may have occurred as a consequence of handling the mummy over time, since no traumatic lesions can be recognized on the final segment of the spine. Traumatic injuries in the form of perimortem fractures are found on the posterior extremities affecting both femora and the right tibia. Although the characteristics of the very fractures cannot exclude that they have preceded death, their distribution, which follows the same direction in all three bones, suggests that the fractures occurred while the animal was already in the respective position. Although many studies have revealed the unnatural and violent death of mummified animals only after radiological examination and interpretation of fractures, this was not the case in this mummy. Most probably, the fractures occurred after death as a consequence of forcefully positioning the cat into the posture in which it was later mummified. However, when taking into consideration the fact that the anterior parts of the body (especially of the head) are missing, the possibility cannot be ruled out that the "Zagreb cat" was killed before mummification was performed.

jim periodima, mačkama pripisivala značajna religijska uloga zbog koje su bile čuvane i obožavane, s vremenom su i one postale tek usputnim objektom trgovine životinjskim mumijama. Upravo su u periodu između 332. i 30. god. pr. Kr. mačke počele biti uzgojene s jedinom namjenom da se prinose kao darovi u hramove božice Bastet. Najveći broj mačaka mumificiranih u tom periodu obuhvaćao je mlade životinje i mačiće dobi između 2 i 4 mjeseca, koji su najčešće namjerno ubijeni kako bi ih se moglo brzo i jednostavno mumificirati za potrebe religijskog tržišta.

Iako veliki broj mumija mačaka otpada na lažne mumije, mumija koja se danas čuva u Arheološkom muzeju u Zagrebu predstavlja primjer gotovo kompletne mačke, mumificirane u skvrčenom, vjerojatno, ležećem položaju. Taj položaj odskaje od puno češćeg - sjedećeg položaja u kojemu su mumificirani posmrtni ostaci većine drugih mačaka porijeklom iz drevnog Egipta.

Mumija mačke / Cat mummy

CT mumijemačke / CT of cat's mummy



The mummy of the “Zagreb cat” is one in a long line of cats mummified in the course of centuries in Ancient Egypt. Although in earlier periods a significant religious role was attributed to cats, which were therefore guarded and worshipped, over time they became merely a casual object in the trade of animal mummies. It was exactly in the period from 332 to 30 BC that cats started being reared with the only purpose of being offered as gifts in the temples of the goddess Bastet. The largest number of mummified cats in that period included young cats and kittens between 2 and 4 months, that were mostly killed on purpose as they could easily and quickly be mummified for the needs of the religious market.

Although a large number of cat mummies dating back to Ancient Egypt are fake, the mummy stored at the Archaeological Museum in Zagreb is an exemplar of an almost complete cat mummified probably lying in a cramped position. This position deviates from the much more frequent sitting one in which most Ancient Egypt cat remains were mummified.

Mumija krokodila / Crocodile mummy

CT mumije krokodila / CT of crocodile's mummy



Ostaci mladunaca krokodila

Drugi smotuljak doveden na radiološku obradbu na Zavod za dijagnostičku i intervencijsku radiologiju Kliničke bolnice Dubrava, bio je omotan tkaninom i dodatno osiguran konopcima duž cijele svoje dužine. Veličina i vretenast oblik smotuljka, s prednjim širim i stražnjim užim krajem, sugerirao je da sadržava mumificirano tijelo mladog krokodila.

Mumificiranje krokodila u drevnom Egiptu bio je rasprostranjen proces, povezan s kultom dvaju značajnih egipatskih božanstva - boga plodnosti - Sebeka te samog boga Sunca - Ra. Krokodili su tijekom stoljeća bili slavljani sa strahopoštovanjem, toliko da se i mumifikacija osoba ubijenih od tih gmazova provodila na način različit od one "običnih" ljudi. S vremenom je, ipak, minuciozna i bogata tradicija mumificiranja krokodila podlegla velikoj potražnji votiva te se pretvorila u rutinski posao u kojemu je kvantiteta zamijenila kvalitetu. Postupno i sve češće su se mumifikacijskom procesu prinisili mladunci krokodila i razni gušteri, dok je broj odraslih, detaljno mumificiranih i ukrašenih životinja postajao sve manji.

Radiološka analiza smotuljka čuvanog u Arheološkom muzeju u Zagrebu, razotkrila je da se radi upravo o jednom od brojnih primjera lažnih krokodilskih mumija. Ispod slojeva tkanine ne nalazi se tijelo jednog krokodila, već mješavina kosti i zbijena tijela krokodilskih mladunaca, od kojih su neki potpuno artikulirani i cjeloviti, dok su drugi prisutni tek fragmentarno. Osim koštanih ostataka mladih krokodila, ispod tkanine nalazi se velika količina organskog materijala, vjerojatno trske, koja otežava iščitavanje radiološke snimke. Konačni broj ostataka nije moguće utvrditi, no sa sigurnošću se unutar smotuljka raspoznaje minimalno sedam mladih krokodila (temeljem broja uočenih lubanji), koji potvrđuju kasniju egipatsku tradiciju lošijeg mumificiranja krokodila.

Remains of a crocodile hatchling

The second wrap-up taken for radiological processing to the Institute of Diagnostic and Intervention Radiology of the Dubrava Clinical Hospital was wrapped in linen and additionally strengthened with cords along its whole length. The size and the spindly shape of the bundle, with a broader front and a more narrow rear, suggested that it contains the mummified body of a young crocodile.

The mummification of crocodiles in Ancient Egypt was a widespread process related to the cult of two significant Egyptian deities: the god of fertility Sebek and the Sun god Ra himself. Over the centuries, crocodiles were worshipped with awe so that even the mummification of humans killed by those animals was carried out in a different manner than the one of "common" people. Over time however, the meticulous and rich tradition of crocodile mummification was overcome by the huge demand for votive offerings turning mummification into a routine business in which quantity replaced quality. The number of crocodile hatchlings and various lizards that underwent mummification was gradually increasing, while the number of adult, meticulously mummified and adorned animals decreased.

Radiologic analysis showed that the wrap-up stored with the Archaeological Museum in Zagreb was one of the numerous fake crocodile mummies. Below the linen layers no crocodile body was found but a mixture of bones and crammed bodies of crocodile hatchlings, some of which were fully articulated and entire, while others were represented just by few bone fragments. Apart from the bone remains of young crocodiles, underneath the linen a huge quantity of organic material, probably cane, was found, which limited the analysis of radiologic images. Although the exact number of individuals could not be established in the wrap-up, what could be recognized with certainty were at least seven young crocodiles (based on the number of skulls present). Hence, this "mummy" bundle confirmed the later Egyptian tradition of less meticulous crocodile mummification.

Lažna mumija ptice ibis

I u slučaju treće analizirane mumije, oblik mumificiranog tijela sugerirao je o kojoj se životinjskoj vrsti radi. Čunjasti svežanj, omotan u vrlo dobro očuvane zavoje, podsjeća svojom formom na poznate primjere mumificirane egipatske ptice-ibisa, koja se smatra la zemaljskom manifestacijom boga Thotha. S obzirom na stanje vanjskog omota, dalo se naslutiti da su pakirani ostaci jednako tako dobro očuvani.

Radiološka je analiza, ipak, opovrgla početna razmišljanja. Razlog tome bila je prisutnost većeg broja razasutih kosti bez ikakve prirodne strukture ili održanog anatomskog odnosa. Sama arhitektonika, ukoliko je ikad postojala, potpuno je narušena. U analiziranom smotuljku nalaze se većinom duge kosti, koje pripadaju razredu ptica. Ipak, teško je utvrditi jesu li iste stvarno posmrtni ostaci ptice ibisa.

Sudbina ptice ibis bila je slična onoj egipatskih mačaka. Iako u početku slavljene kao utjelovljenje značajnog i voljenog božanstva, naknadno su se koristile kao žrtveni prinosi istome bogu. U nekropolama posvećenim bogu Thothu cvjetala je trgovina mumijama ibisa, čemu u prilog govori podatak da drevno groblje Saqqara sadrži mumificirane ostatke gotovo 500 000 ibisa. Zbog velike potražnje za njihovim mumijama, mumificiranje se sve češće provodilo na mladim ubijenim pticama na način da ih se jednostavno umakalo u katran, koji je služio kao trenutačno mumifikacijsko sredstvo. Kasnije su, kao što se dogodilo i kod ostalih životinjskih vrsta, originalne mumije zamijenjene lažnima, čiji je predstavnik navodna ibisova mumija Arheološkog muzeja u Zagrebu.

Lažna mumija ptice ibis / The fake ibis mummy



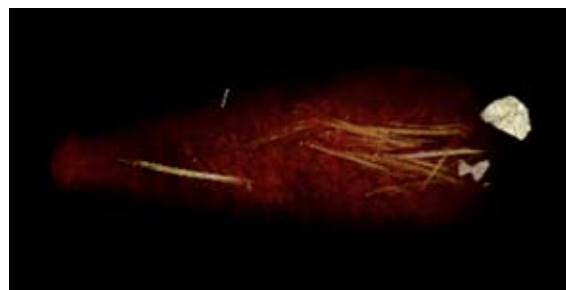Fake ibis mummy

Also in the case of the third mummy the shape of the body suggested the animal species it belonged. The conical bundle wrapped in very well preserved bandages, reminds with its form the famous examples of mummified Egyptian bird ibis that was considered as an earthly embodiment of the god Thoth. Based on the state of its outer wrapping, it was concluded that the packed remains are also well preserved. Radiologic analysis however refuted the initial considerations, because the bundle contained only scattered bones with no anatomical structure preserved. The analysed wrap-up contained mostly long bones belonging to the species of birds. However, it is hard to establish whether the mortal remains are indeed those of an ibis.

In Ancient Egypt, the fate of the ibis was similar to that of cats. Although they were initially worshipped as the embodiment of an important and loved deity, later they were used as sacrifice offerings to those very same gods. In the necropolises devoted to the god Thoth trade in ibis mummies was flourishing, which is confirmed by the fact that the ancient Saqqara cemetery contains mummified remains of almost 500,000 ibises. Due to the huge demand for ibis mummies, mummification was increasingly often performed on young killed birds simply by plunging them into tar that functioned as an instantaneous mummification agent. Later, like in the case of other animal species, fake mummies replaced original ones and a representative of that kind is the alleged ibis mummy of the Archaeological Museum in Zagreb.

CT VRT rekonstrukcija lažne mumije ptice ibis

CT VRT reconstruction of the fake ibis mummy



Hrpa kostiju nepoznatog porijekla

Četvrta, navodno životinjska, mumija koja se čuva u Arheološkom muzeju u Zagrebu svojim vanjskim izgledom ne podsjeća niti na jednu poznatu mumificiranu životinjsku vrstu. Kao što je već prije opisano, često sam oblik smotuljka u kojemu se nalazi mumija može sugerirati o kojoj se životinjskoj vrsti radi, kao u slučaju ibisa i krokodila. U ovom primjeru, takva poveznica između oblika i moguće životinjske vrste nije pronađena.

Radiološka analiza ostataka, potvrdila je pretpostavke proizašle iz vanjskog pregleda navodne mumije. Ispod brojnih zavoja, rendgenske zrake nisu naišle na tijelo ikakve životinje, nego isključivo na nakupinu kosti. Kostiju su gusto raspoređene po čitavoj duljini smotuljka te se u najvećem dijelu preklapaju i otežavaju očitavanje radiološke snimke. Detaljnijim pregledom slike prepoznaje se dio koštanih elemenata (kralješci, rebra, duge kosti). S obzirom na veličinu samog smotuljka i neuočenih epifiznih krajeva u većem broju dugih kosti, daje se naslutiti da su iste pripadale vrlo mladim i nezrelim životinjama.

I u ovom slučaju, potvrđena je egipatska tradicija proizvodnje lažnih votivskih mumija, koje su, nerijetko, bile sačinjene od niza neartikuliranih i anatomski nepovezanih koštanih elemenata.

A pile of bones of unknown origin

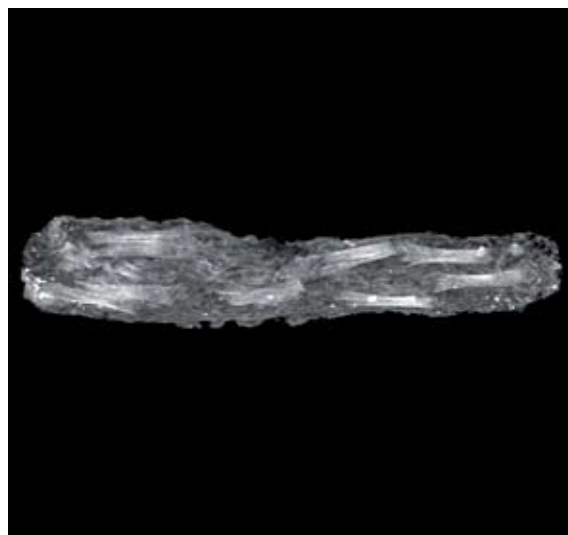
In terms of its appearance the fourth allegedly animal mummy stored with the Archaeological Museum in Zagreb does not remind us of any known mummified animal species. As already mentioned, often the form of the wrap-up containing the mummy could suggest which animal it contained, as was the case with the crocodile or the ibis. In this example however, no link between the form of the bundle and the possible animal species it contains could be established.

Radiologic analysis of the remains confirmed the hypothesis made based on the external examination of the alleged mummy. Underneath the numerous bandages, x-rays did not evidence the body of an animal but only a pile of bones. Bones were densely arranged along the whole length of the wrap-up and mostly overlapped making thus the interpretation of radiologic images more difficult. By looking at the images thoroughly, fragments of some bones (vertebrae, ribs, long bones) could be identified. When considering both the size of the very wrap-up and the impossibility of identifying epiphyses in most long bones, the fact could be inferred that they belonged to very young, immature animals.

The Egyptian tradition of producing fake votive mummies often made of unarticulated and anatomically unrelated bones was confirmed also in this case.



Hrpa kostiju / The pile of bones



CT hrpe kostiju / CT of the pile of bones

Nepoznata životinja unutar kutijice za guštere

Osim samog oblika mumificiranog tijela, postoje i drugi elementi koji mogu sugerirati o kojoj se mumificiranoj životinjskoj vrsti radi. Jedan od tih je sarkogaf ili kutija u kojoj je tijelo životinje pohranjeno. Sarkofazi životinja su često bili građeni tako da imaju oblik umrle životinje (mačke, psa itd.) ili oslikani sukladno sadržaju. Drvene kutije u kojima su životinje pohranjivane isto tako su imale natpis ili sliku životinje koja se u njima nalazila. Tako je peta analizirana mumija pohranjena u kutijici koja je najvjerojatnije bila namijenjena sahranjivanju malih gmazova - guštera.

Radiološka obradba male kutije bila je otežana dimenzijom iste. Ostaci pohranjeni u kutiji izuzetno su male veličine i prema tome neprikladni i atipični za analizu klasičnim rendgenom ili kompjutoriziranom tomografijom koji su inače namijenjeni čovjeku. Rezultati dobiveni tim dvjema metodama nisu zadovoljavajući u tome što nisu omogućili raspoznavanje životinjske vrste pohranjene u drvenoj kutijici. Iako se uočavaju koštani elementi, savijenost životinjice i lošija očuvanost, dodatno otežavaju uspješnu analizu ostataka. Zbog toga analiza pete životinjske mumije nije mogla opovrgnuti niti potvrditi primarnu pretpostavku da se radi o ostacima guštera. U razjašnjavanju tog pitanja potrebno je planirati novi pristup, koji bi uključivao mikro-CT, slikovni aparat namijenjen obradbi malih objekata, među kojim bi mogla spadati i peta "zagrebačka" životinjska mumija.

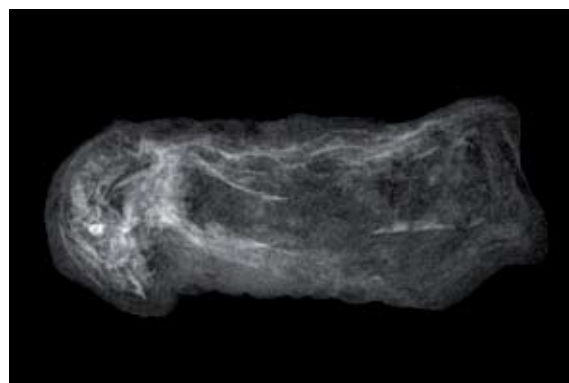

Nepoznata životinja / Unknown animal

Unknown animal inside a small lizard box

Apart from the very shape of the mummified body, there are also other elements that may suggest the animal species contained in the bandages. One of those elements is the sarcophagus or box in which the body is stored. Animal sarcophagi were often made in the shape of the dead animal (of a cat, a dog etc.) or displayed paintings based on the content. Wood boxes, in which part of the mummified animals were stored, had also an inscription or a drawing of the animal found inside. The fifth analysed mummy was stored in a small box, which was most probably meant for burring small reptiles – lizards.

Radiologic processing of the small box was made difficult due to its dimension. The remains stored in the box were exceptionally small and were thus inadequate both for classical x-ray analysis and CT, which are meant for humans. The results obtained with those two methods are not satisfactory, as they did not enable the identification of the animal species stored in the small wood box. Although bone elements could be identified, the bent shape of the little animal and the poor state of preservation additionally complicated the successful analysis of remains. Therefore, the analysis of the fifth animal mummy could neither refute nor confirm the initial hypothesis that it belongs to a lizard. In trying to clarify this issue, a new approach should be considered including a micro-CT, an imaging device meant for processing small objects, like the fifth "Zagreb" animal mummy.



CT nepoznate životinje / CT of the unknown animal

Dvije ruke u potrazi za identifikacijom

Jedna od karakteristika mumija jest ta da, iako prkose vremenu zadržavajući intaktno meko tkivo i organe, njihovo tijelo podliježe poslijesmrtnim promjenama koje izmjenjuju njihovu strukturu i izgled. To dovodi do toga da se fizionomija i tjelesne osobine mumija mijenjaju kroz vrijeme, te da njihov sadašnji izgled, položaj tijela i izraz lica ne odgovaraju onima koji su ih pratili u vrijeme smrti. Neke od poslijesmrtnih promjena zahvaćaju mišiće tijela čija je relaksacija spriječena djelovanjem mumifikacijskih agenasa. Zbog toga oni poprimaju “neprirodno kontrahirani” (ta je skvrčenost isto proizvod poslijesmrtnih promjena) i nerijetko dovode do formiranja grimasa na licu mumija, za koje se nekoć smatralo da odražavaju izraz lica pokojnika prije smrti. Osim grimasa na licu, promjene koje zahvaćaju mišiće dovode do neprirodnog položaja tijela, skvrčenih šaka itd. Osim toga, zbog poslijesmrtnog procesa propadanja pigmenta (eumelanina) odgovornog za crnu/smeđu boju kose te očuvanja puno otpornijeg “crvenog” pigmenta, nekoć se pogrešno zaključivalo da je većina mumija bila za života crvenokosa. Određivanje spola mumija analizom spolnih organa i prisutnosti dojki često je otežano zbog poslijesmrtnih promjena i propadanja tih organa. Uz promjene na razini mišića, kose i organa, promjene zahvaćaju i boju kože koja se kroz vrijeme mijenja, poprimajući najčešće tamne i zagasite tonove. Zbog velikog broja poslijesmrtnih promjena, u koje spadaju i gore opisani procesi, nerijetko se događa da se neki mumificirani dijelovi tijela ne mogu prepoznati kao takvi ili se ne mogu dovesti u vezu s ljudskim podrijetlom.

U Arheološkom muzeju u Zagrebu čuvaju se dvije mumificirane šake za koje je postojala dvojba pripadaju li ljudima ili ostalim primatima. S obzirom na to da je mumificiranje majmuna, pogotovo pavijana, bio raširen postupak u drevnom Egiptu te s obzirom na promijenjen izgled mumificiranih “zagrebačkih šaka”, postavilo se pitanje o njihovom podrijetlu.

Two hands in pursuit of identification

Although the main characteristic of mummies is the preservation of soft tissues, their body however undergoes a number of postmortem changes that affect and alter their appearance. As a consequence of these changes, the appearance of mummies, as well as the position of their bodies and the facial expressions does not correspond to those they had at the moment of death. Some post-mortem changes involve body muscles, whose relaxation is prevented due to mummification agents. That is why mummies appear “unnaturally contracted” (their contraction is also a result of postmortem changes) and often-present facial grimacing - once believed to show the facial expression of the deceased before death. Apart from facial grimaces, changes affecting muscles lead also to an unnatural position of the body, contracted fists etc. Moreover, due to the postmortem decay of the pigment that gives hair its black/brown colour (eumelanin) and preservation of the much more resistant “red” pigment, the wrong conclusion was drawn once that most mummies were red-haired in their lifetime. Defining gender in mummies by analysing genitals and the presence of breasts was often aggravated by post mortal changes and organ decay. Alongside changes affecting muscles, hair and organs, there are also those concerning the colour of the skin that darkens over time. As a consequence of the numerous post mortal changes affecting mummies, the identification of some mummified body parts is made impossible or no link to their human origin can be established.

In the Archaeological Museum in Zagreb two mummified hands are stored which gave rise to doubts as to whether they belonged to humans or to other primates. Based on the fact that the mummification of monkeys, especially baboons, was a widespread practice in Ancient Egypt, and based on the particular appearance of mummified “Zagreb hands”, the question concerning their origin was raised.

Zahvaljujući postojanju očitih razlika u morfologiji kosti ljudi i životinja, razlikovanje njihovih ostataka rijetko kada može ostaviti dvojbe ukoliko se radi o čitavim skeletnim elementima. Ipak, postoje slučajevi gdje djelomično očuvani životinjski ostaci mogu biti zamijenjeni s ljudskima. Jako čest primjer jest medvjeda šapa, čije kosti, njihova morfologija i međusobni odnos dovode do toga da nerijetko bivaju zamijenjene za ljudske. U slučaju šaka primata problem može biti sličan, jer majmunška šaka nalikuje u većem broju karakteristika ljudskoj. Poznavanje anatomije ljudske šake te evolucijskih mehanizama koji su doveli do razlika između ljudskih i životinjskih šaka (pogotovo onih ostalih primata) od značajne je koristi u njihovom diferenciranju.

Ruke koje se čuvaju u Arheološkom muzeju u Zagrebu karakterizirane su promjenama tipičnim za mumificirana tkiva: koža koja ih prekriva je zagasite pepeljaste boje, očuvanih noktiju, s kostima doručja koje izbijaju ispod nje te elongiranim, skupljenim/skvrčenim prstima. Same promjene daju šakama gotovo neljudski izgled što je i potaklo sumnju u njihovo pravo podrijetlo. Ipak, detaljnijim pregledom uočavaju se svojstva specifična za ljudsku vrstu, koja se dodatno potvrđuju radiološkim snimkama.

Jedna od osnovnih karakteristika koja razlikuje ljudsku šaku od ostalih životinja jest bogatstvo kretnji koje može izvesti, a rezultat je evolucijskog "oslobađanja" ruku i sposobnosti oponiranja palca drugim prstima. Iako je ljudska šaka slična majmunskoj po morfologiji kosti, evolucijske promjene koje su je zahvatile omogućuju njihovo razlikovanje. Tipična majmunška šaka karakterizirana je malim palcem i dugim zakrivljenim prstima. Kod čovjeka se evolucijom palac produžuje, a prsti se skraćuju i gube karakterističnu zakrivljenost. Dodatno, koštani vršci prstiju (apikalni dijelovi distalnih falangi) postaju širi, doručna (metakarpalna) kost malog prsta se zadebljava, a njezina baza povećava. Te su promjene praćene i promjenama na razini zglobnih površina, zglobova te mišića koji reguliraju pokrete prsta. Prateći spomenute

Thanks to the existence of obvious differences in the morphology of human and animal body parts, telling between their remains can rarely leave some doubts if entire skeletal elements have been preserved. Still, there are cases in which partly preserved animal remains may be mistaken for human ones. A bear's paw is often taken as an example thereof, because its bones can be often mistaken for human. A similar problem may occur with primates' hands, as the hands of monkeys present even a higher number of similar features to those of humans. Knowledge of the anatomy of human hands and of the evolution mechanisms that produced the differences between animal hands (especially those of other primates) and human ones is of major importance for being able to differentiate them.

The hands stored with the Archaeological Museum in Zagreb display features typical of mummified tissues: the skin covering them is of a dark ash-like colour, the nails are preserved, metacarpal bones emerge from under the skin and the fingers are elongated and contracted. Those very changes convey to the hands an almost inhuman appearance, which gave rise to doubts concerning their origin. However, by thoroughly analysing them and relying on radiologic imaging data, human features could be identified.

One of the major factors responsible for allowing the differentiation between the hands of a human and that of animals is the richness of movements the human hand can perform which is the result of the evolutionary "liberation" of the hands and of the ability to oppose the thumb to other fingers. Although the shape of the constituent bone elements of the human hand is similar to that of other primates, they may be differentiated based on the evolutionary changes that affected them.

The typical hand of a monkey features a small thumb and long curved fingers. In the evolution process of humans the thumb became elongated and the fingers shorter and less curved losing the distortion typical of monkeys. In addition, evolution changes af-


razlike na radiološkim snimkama moguće je, prema tome, zaključiti je li šaka pripada čovjeku ili majmunu.

Takva vanjska i radiološka obradba provedena je na dvije šake iz Arheološkog muzeja u Zagrebu, nakon čega je zaključeno da su obje ljudskog podrijetla. Iako se vanjskim pregledom čini da je dlan prve šake izrazito izdužen (karakteristika majmunskih šaka), na njoj se ipak uočavaju sve karakteristike tipične za ljudsku šaku odrasle osobe. Za razliku od prve šake, druga šaka puno je manje veličine. Svi su prsti skvrčeni (što je dalo šaci neprirodan izgled i otežalo dobivanje adekvatne radiološke snimke), a gotovo pola prstenjaka nedostaje. Ipak, karakteristike petog prsta i veličina palca potvrđuju da se radi o ljudskoj šaci. Osim toga, radiološkom analizom utvrđeno je da su kosti nepotpuno razvijene što upućuje da se radi o šaci djeteta. Prisutnost tek dviju karpalnih kosti (dvije kratke kosti ručja na bazi šake) ukazuje na to da ostale još nisu okoštale, po čemu se zaključuje da je šaka vjerojatno pripadala dvogodišnjem djetetu.

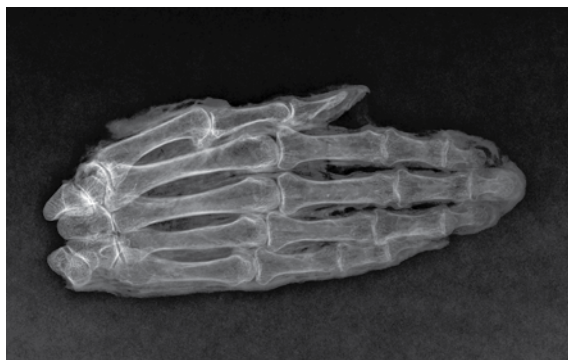affected bone fingertips (apical parts of distal phalanges) that become wider, and the 5th metacarpal bone that become thicker and its base bigger. These changes are accompanied by changes at the level of joint surfaces, joints and muscles regulating finger movements. By observing those changes in radiologic images it is possible to conclude whether a hand belongs to a human or a monkey.

The two hands of the Archaeological Museum in Zagreb were subject to such external examination and radiological processing leading to the conclusion that they are both of human origin. Although by means of external examination the palm of the first hand seemed significantly elongated (a typical feature of monkeys' hands) it still displayed all characteristics typical of adult human hands. Unlike the first hand, the second one is of a much smaller size. All fingers are contracted (conveying to the hand an unnatural appearance and aggravating the possibility of obtaining an adequate radiologic image) and almost half the ring finger is missing. However, both the morphology of the fifth finger and the size of the thumb confirm its human origin. Radiologic imaging showed that the fingers are not fully developed indicating that the hand belonged to a child. The presence of only two carpal bones (two short bones at the base of the hand) indicates that the other bones did not ossify yet, which allows us to approximate that the child was two years old.

Ruka
Hand



CT ruke
CT of the hand



Zaključak

Arheološki muzej u Zagrebu čuva zanimljive primjere mumija i mumificiranih dijelova tijela koji pripadaju periodu drevnoga Egipta. Zbirka kojoj pripadaju životinjske mumije dokumentira različiti odnos kojeg su Egipćani njegovali prema njima i njihovom mumificiranju. Dok u dva slučaja nalazimo posmrtnu ostatku gotovo cjelovitih životinja (mačke i neidentificirane životinje unutar drvene kutijice), mumija koja sadržava ostatke mladunaca krokodila svjedoči o postupnom smanjenju brige koja se ulagala u mumificiranje životinja. Navodna mumija ibisa potvrđuje promjenu načina mumificiranja životinja u Egiptu koji je uslijedio prilikom procvata životinjskih nekropola na egipatskom teritoriju i velike potražnje za životinjskim votivima, kada su autentične mumije životinja zamijenjene jeftinijim kopijama. Iako zagrebačka "mumija ibisa" svojim vanjskim oblikom u potpunosti odgovara onom originalno mumificiranih ptica, radiološka analiza razotkrila je da je smotuljak ispunjen tek malobrojnim raspršenim i anatomski nepovezanim kostima. U kategoriju lažnih mumija životinja može se ubrojiti i smotuljak koji sadržava hrpu kostiju, koji, niti vanjskim oblikom a niti unutarnjom analizom, nije razotkrio kojoj životinjskoj vrsti pripada. Slijedom rečenog, životinjska kolekcija Arheološkog muzeja u Zagrebu realno predstavlja razvoj i dekadenciju postupka mumificiranja životinja u drevnome Egiptu.

Osim toga, životinjska zbirka Arheološkog muzeja predstavlja značajan doprinos paleoradiološkoj interpretaciji mumificiranih ostataka, jer nudi svakom stručnjaku izazov diferenciranja i prepoznavanja koštanih elemenata i životinjskih vrsta na radiološkim snimkama sa smetnjama uzrokovanim neprikladnim položajem uzorka i pridruženim artefaktima. Radiološka analiza mumija obogatila je dosadašnja saznanja o zbirci Arheološkog muzeja u Zagrebu, kao što je doprinijela boljem shvaćanju i interpretaciji stare i značajne tradicije rukovanja s poslijesmrtnim ostacima ljudi i životinja, koju nazivamo mumificiranjem.

Conclusion

The Archaeological Museum in Zagreb stores interesting exemplars of mummies and mummified body parts. The collection documents the different relations Egyptians fostered towards animals and their mummification. While in two cases the mortal remains of almost entire animals are found (cats and unidentified animals inside a small wood box), the mummy containing remains of crocodile hatchlings testifies the gradual decrease in the care employed in animal mummification. The alleged ibis mummy confirms the change in the way animal mummification was performed in Egypt. In fact, as a consequence of the flourishing of animal necropolises on Egyptian territory and the increasing demand for animal votives, authentic animal mummies were replaced by cheaper copies. Although in terms of its external form the Zagreb "ibis mummy" entirely corresponds to that of the mummified bird, radiological analysis revealed that the wrap-up is packed with only few scattered and anatomically unrelated bones. Another bundle with a pile of bones, whose origin could not be determined even after external and internal analysis, also represents to the category of fake animal mummies. When taking into account everything that has been said so far, the conclusion arises that the animal collection of the Archaeological Museum in Zagreb documents the development and fall of the mummification practice in Ancient Egypt. It represents a significant contribution to the interpretation of mummified remains as it poses to any expert the challenge of differentiating and recognizing bones and animal species on the basis of radiologic images with interferences caused by inadequate positions of the exemplars and the presence of artefacts. Finally, the radiologic analysis of mummies has enriched the cognitions about the collection of the Archaeological Museum in Zagreb and it has contributed towards understanding and interpreting the ancient and significant tradition of handling human and animal mortal remains, which we call mummification.

Aiello L, Dean C. (2002) *An Introduction to Human Evolutionary Anatomy*. London: Elsevier

Aufderheide AC. (2003). *The Scientific Study of Mummies*. New York: Cambridge University Press

Bernschneider-Reif S, Alt KW; Meier S, Ruhli F, Rosendahl W. Egyptian Mummies- The Merck Archives in Darmstadt. In: Wiczorek A, Rosendahl R (eds) (2010) *Mummies of the world*. Munich: Prestel: 319-322.

Brogdon BG. Radiological Identification: Anthropological Parameters. In: Thali MJ, Viner MD, Brogdon BG (eds) (2011). *Forensic Radiology*. Boca Raton: CRC Press

Buckley SA, Clark KA (2004). Evershed RP. Complex organic chemical balms of Pharaonic animal mummies. *Nature*; 431:294-299.

Clark MA, Worrell MB, Pless JE. Postmortem Changes in Soft Tissues. In: Haglund WD, Sorg MH (eds) (1997). *Forensic Taphonomy: The Postmortem Fate of Human Remains*. Boca Raton: CRC Press.

Gnudi G, Volta A, Manfredi S, Ferri F, Conversi R (2012). Radiological investigation of an over 2000-year-old Egyptian mummy of a cat. *J Feline Med Surg*; 14: 292-294.

Jackowski C, Bolliger S, Thali MJ (2008). Common and Unexpected Findings in Mummies from Ancient Egypt and South America revealed by CT. *Radiographics*; 28:1477-1492.

Joger U. Natural Animal Mummies on Exhibit at the State Museum of Natural History in Braunschweig, Germany. In: Wiczorek A, Rosendahl R (eds) (2010) *Mummies of the world*. Munich: Prestel: 285-288.

Koenig W (1896). 14 Photographien von Roentgen-Strahlenaufgenommen im Physikalischen Verein zu Frankfurt a. M. Leipzig: Johann Ambrosius Barth.

Lorenzi R (2012). Animals mummified by the millions in Ancient Egypt. *Discovery News*. Dostupno: <http://news.discovery.com/history/mummified-animals-egypt-120106.html> (zadnji pristup: 4. Svibnja 2012)

Lynnerup N (2007). Mummies. *Yearbook of Physical anthropology*; 50: 162-190.

Petrovecki V, Mayer D, Kis I, Slaus M, Strinović D (2006). Ljudski ili životinjski ostaci? *Lijec Vjesn*; 128:238-241.

Rosendahl W, Alt KW, Meier S, Ruhli F. Egyptian Mummies - The Reiss-Engelhorn-Museen Collection. In: Wiczorek A, Rosendahl R (eds) (2010) *Mummies of the world*. Munich: Prestel: 316-319.

Rühli FJ, Chhem RK, Böni T (2004) Diagnostic paleoradiology of mummified tissue: interpretation and pitfalls. *Can Assoc Radiol J*;55:218-227.

The Animal Mummy Database. Dostupno: <http://www.animalmummies.net/index.php> (zadnji pristup: 4. Svibnja 2012)

Velde H (1980). A few Remarks upon the Religious Significance of Animals in Ancient Egypt. *Numen*; 27:76-82.

Young RW (2003). Evolution of the human hand: the role of throwing and clubbing. *J Anat*; 202:165-174.



MUMIJE

znanost i mit

MUMMIES

science and myth

MEDIJSKI POKROVITELJ



Zagreb, 2012.